

BLOOD CELL MORPHOLOGY AND LEUKOCYTE DIFFERENTIAL OF MORELET'S CROCODILE (*Crocodylus moreletii*) (CROCODYLIDAE)

Morfología de células sanguíneas y recuento leucocitario del cocodrilo de Morelet (*Crocodylus moreletii*) (CROCODYLIDAE)

Adrián GUTIÉRREZ-CERVANTES¹, Concepción AHUJA-AGUIRRE¹*, Lorena LÓPEZ-deBUEN¹, Sergio VIVEROS-PEREDO^{1,2}

¹ Facultad de Medicina Veterinaria y Zootecnia, Universidad Veracruzana. Miguel Ángel de Quevedo S/N, Esq. Yáñez, Veracruz, Ver., México.

² El Colibrí de la Antigua, UMA Cacahuatal. La Antigua, Ver., México.

* **For correspondence:** cahuja@uv.mx

Received: 28th February 2020. **Returned for revision:** 05th November 2020. **Accepted:** 25th November 2020.

Associate Editor: Francisco Martínez Pérez

Citation/ citar este artículo como: Gutiérrez-Cervantes, A., Ahuja-Aguirre, C., López-deBuen, L., and Viveros-Peredo, S. (2022). Blood cell morphology and leukocyte differential of Morelet's crocodile (*Crocodylus moreletii*) (Crocodylidae). *Acta Biológica Colombiana*, 27(1), 17-27. <https://doi.org/10.15446/abc.v27n1.85418>

ABSTRACT

The objective of the study was to determine the morphological characteristics of peripheral blood cells (erythrocytes, leukocytes, thrombocytes) and the leukocyte differential count (heterophils, eosinophils, basophils, lymphocytes, monocytes, azurophils) of captive Morelet's crocodiles (*Crocodylus moreletii*) from Veracruz, Mexico. Peripheral blood from 80 apparently healthy farmed crocodiles (39 subadults [19 females, 20 males] and 41 adults [18 females, 23 males]) was examined for morphology through stained blood smears and manual count was used for the leukocyte differential. Blood was collected during the non-breeding ($n = 42$) and breeding ($n = 38$) seasons. Blood examination indicated similar morphological characteristics of blood cells in subadult and adult individuals and in females and males in both seasons. Erythrocytes were the largest blood cells and lymphocytes the smallest. The leukocyte differential count showed that lymphocytes were the most abundant leukocytes and basophils the least numerous. The percentages of some leukocytes showed difference by season (non-breeding and breeding) in subadult and adult males ($p < 0.05$) and by size (subadults and adults) in males and females but only in the non-breeding season ($p < 0.05$). The leukocytes that showed the greatest variation were lymphocytes, heterophils and eosinophils. The knowledge of blood cell morphology and the leukocyte differential count in healthy farmed Morelet's crocodiles will allow the accurate diagnosis of some diseases of captive and wild individuals.

Keywords: Crocodylians, hematology, red blood cells, white blood cells.

RESUMEN

El objetivo del estudio fue determinar las características morfológicas de células sanguíneas periféricas (eritrocitos, leucocitos, trombocitos) y el conteo diferencial de leucocitos (heterófilos, eosinófilos, basófilos, linfocitos, monocitos, azurófilos) del cocodrilo de Morelet (*Crocodylus moreletii*) mantenido en cautiverio en Veracruz, México. Se examinó sangre periférica de 80 cocodrilos aparentemente sanos criados en granja (39 subadultos [19 hembras, 20 machos] y 41 adultos [18 hembras, 23 machos]) mediante frotis sanguíneos teñidos para determinar la morfología celular y mediante conteo manual para el diferencial de leucocitos. La sangre se recolectó durante las temporadas no reproductiva ($n = 42$) y reproductiva ($n = 38$). El examen sanguíneo indicó similar morfología de células sanguíneas en individuos subadultos y adultos, así como en hembras y machos, en ambas temporadas. Los eritrocitos fueron las células sanguíneas más grandes y los linfocitos las más pequeñas. El conteo diferencial de leucocitos mostró que los linfocitos fueron los leucocitos más abundantes y los basófilos los menos numerosos. Los porcentajes de algunos leucocitos mostraron diferencia por época (no reproductiva y reproductiva) en machos subadultos y adultos ($p < 0,05$) y por talla (subadultos y adultos) en machos y hembras sólo en temporada no reproductiva ($p < 0,05$). Los leucocitos que tuvieron la mayor variación fueron linfocitos, heterófilos y eosinófilos. El conocer la morfología de las células sanguíneas y el conteo diferencial de leucocitos en individuos sanos de cocodrilo de Morelet criados en granja permitirá diagnosticar con precisión algunas enfermedades de individuos manejados en cautiverio y también de individuos silvestres.

Palabras clave: Cocodrilianos, glóbulos blancos, glóbulos rojos, hematología.

INTRODUCTION

Crocodylians (crocodiles, caimans, alligators and gharials) are considered keystone species of their ecosystems due to the different roles they play; they might as well serve as potential sentinels of environmental contamination because they tend to bioaccumulate contaminants throughout their long-life span (Milnes and Guillet, 2008; Somaweera et al., 2020). Hence the importance of monitoring the health status of wild crocodylians.

One key aspect to assess the health status of wild species is the evaluation of hematologic parameters. As in other reptiles, crocodylian blood cells are erythrocytes, thrombocytes and leukocytes, all nucleated. Leukocytes are classified as granulocytes (heterophils, eosinophils, basophils) and mononuclear cells (lymphocytes, monocytes, azurophils). Heterophils are the equivalent of mammalian neutrophils; eosinophils and basophils have no clear function in reptiles; lymphocytes and monocytes have similar morphology and function to those of mammals; azurophils are unique to reptiles with similar morphology and function to granulocytes and monocytes (Montali, 1988; Dotson et al., 1995; Alleman et al., 1999; Stacy et al., 2011).

In crocodylians, the examination of blood cell morphology through the evaluation of stained peripheral blood smears, along with the determination of the leukocyte differential count, are essential for the accurate diagnosis of some pathological processes (Campbell, 2004; Rossini and García, 2010). Any change in the morphology of peripheral blood cells can be an indicator of specific diseases (Stacy et al., 2011; Campbell, 2012).

Blood cell morphology varies greatly among reptile species, including those within the same genus (Stacy and Whitaker, 2000; Stacy et al., 2011). In addition, factors such as age, environmental conditions, particularly variations in temperature, season of the year and wild or captive status, can affect several components of the reptile hemogram (Stacy, 2011). In crocodylians, blood cells have been characterized in the American alligator (*Alligator mississippiensis* Daudin, 1802) (Glassman et al., 1981; Mateo et al., 1984), Salt-water crocodile (*Crocodylus porosus* Schneider, 1801) and Australian fresh-water crocodile (*Crocodylus johnstoni* Krefft, 1873) (Canfield, 1985), Spectacled caiman (*Caiman crocodilus* Linnaeus, 1758) (Rossini and García, 2010), Broad-snouted caiman (*Caiman latirostris* Daudin, 1802) and Yacare caiman (*Caiman yacare* Daudin, 1802) (Moura et al., 1999; Mussart et al., 2006; Zayas et al., 2011).

Nonetheless, for Morelet's crocodile (*Crocodylus moreletii* Duméril and Bibron, 1851), there is no information on blood cell morphology, either in wild or in captive individuals and despite its ecological and economic importance. The Morelet's crocodile is native to Mexico, Guatemala and Belize and is one of the two crocodile species extant in Mexico. In the first half of the 20th century, overhunting of this crocodile for its skin resulted

in severe population declines (Platt and Thorbjarnarson, 2000; Cedeño-Vázquez et al., 2012). In the 1970s, the Mexican government banned its hunting and decreed its protection and conservation, and populations gradually started to recover and thrive (Platt and Thorbjarnarson, 2000; Sánchez-Herrera et al., 2011). In the early 1980s, the International Union for Conservation of Nature (IUCN) Red List of Threatened Species included the Morelet's crocodile with the status of Endangered (Platt and Thorbjarnarson, 2000; Cedeño-Vázquez et al., 2012).

Currently, the Morelet's crocodile is legally protected in Mexico (Secretaría de Medio Ambiente y Recursos Naturales [SEMARNAT], 2010), has the status of Least Concern in the IUCN Red List (International Union for Conservation of Nature [IUCN], 2019) and is included in Appendix II of the Convention on International Trade in Endangered Species of Wild Fauna and Flora with a zero quota for commercial trade in wild specimens (La Convención sobre el Comercio Internacional de Especies Amenazadas de Fauna y Flora Silvestres [CITES], 2019). Because of this, the legal use of the Morelet's crocodile for commercial purposes in Mexico is restricted to individuals raised in captivity in breeding farms known as Wildlife Conservation Units (Sánchez-Herrera et al., 2011; Cedeño-Vázquez et al., 2012); there, individuals are also used for research purposes regarding farming and captive management.

Since blood cell morphology varies greatly among reptiles within the same genus and many factors influence the components of their hemogram, we hypothesized that the Morelet's crocodile would have some particularities regarding other crocodylians. Therefore, the objective of this study was to describe the morphological characteristics of peripheral blood cells and to determine the leukocyte differential count of healthy farmed Morelet's crocodile females and males, subadults and adults in the breeding and non-breeding seasons, to have information that can be used as a reference to assess the health status of captive and wild crocodiles. In the latter, this information could also be used to evaluate the effect of environmental contaminants on their hematologic parameters and therefore on the health of wild populations and their ecosystems.

MATERIALS AND METHODS

Animal experimentation was performed in compliance with the guidelines of the Bioethics and Animal Welfare Commission from the School of Veterinary Medicine, University of Veracruz (Facultad de Medicina Veterinaria y Zootecnia, Universidad Veracruzana) in Veracruz, Mexico.

Study characteristics and experimental animals

The study was carried out in Veracruz, Mexico (19°22' N and 96°22' W, at 20 m.a.s.l.) at Cacahuatal Wildlife Conservation Unit, which is a closed-cycle breeding farm

for rearing Morelet's crocodiles for commercial and conservation purposes. The study was conducted in the non-breeding (November 2018) and breeding (March 2019) seasons. All the crocodiles included in the study were born at the farm and had been raised for their skin and meat.

Eighty apparently healthy Morelet's crocodiles were evaluated. Of them, 39 individuals were subadults (1.01 m to 1.50 m length; 6 – 7 years-old; 8.8 ± 2.1 kg weight; 19 females and 20 males) and 41 adults (≥ 1.51 m length; ≥ 8 years-old; 30.3 ± 11.8 kg weight; 18 females and 23 males). Of the 80 crocodiles, samples were taken from 20 subadults (ten females and ten males) and 22 adults (ten females and 12 males) in the non-breeding season ($n = 42$), and 19 subadults (nine females and ten males) and 19 adults (eight females and 11 males) in the breeding season ($n = 38$). The crocodiles captured in the non-breeding season were not recaptured in the breeding season.

All individuals came from the general population. Crocodiles were kept separated by size (subadults and adults) in concrete enclosures containing both females and males, in a stock density depending on their size. The enclosures had galvanized fencing of 1.6 m height as a barrier in their surroundings. The dimensions (length x breadth x height) of each enclosure were 18 m x 8 m x 1.4 m. Each enclosure had a water pool of 17 m x 6 m x 1.4 m filled with water at 80 cm depth, a cement basking area at each side and a shaded area of 12 m x 1.5 m.

During the study all crocodiles received 8 – 10 % of their live weight of a commercial feed (40 % crude protein) one to four times a week, depending on the weather. On such days, feed consumption was evaluated to assure that the amount given was sufficient to satisfy their appetite. Crocodiles were routinely dewormed every four months with mebendazole (40 mg/kg weight) mixed with food; for this study, animals were dewormed two weeks before blood sampling.

Throughout the study, general management at the farm included daily monitoring of all the animals, partial replacement of the water from the enclosures thrice a week and washing and disinfection of the enclosures with complete replacement of the water every three weeks, in all the cases without handling the animals.

Animal handling and blood sample collection and processing

Crocodiles were captured at random from their enclosures. Once captured, they were physically restrained in ventral recumbency and their jaws were taped shut to assure their own and the handlers' safety. Each individual was digitally palpated in the cloaca for sex identification and was examined visually for bite wounds, skin lesions and signs of trauma or illness to avoid including sick individuals or individuals in poor body condition.

Once restrained, 2 to 3 mL of blood were drawn from each animal from the post-occipital venous sinus with a sterile 21-ga needle and a 5 mL syringe, previously disinfecting the area with iodine solution. Blood drawn was immediately transferred into 5 mL tubes containing ethylenediaminetetraacetic acid (EDTA) as anticoagulant. Samples were refrigerated and transported to the laboratory, where four blood smears were made from each of the 80 samples (one sample per crocodile) within 4 – 5 hours of collection. Blood smears were made on microscope slides and stained with Romanowsky-type staining (Hemocolorante Rápido Hycel®, Hycel de Mexico, S.A. de C.V.).

Finally, each crocodile was measured using a flexible measuring tape to know its total length and was weighed using a harness around the four limbs attached to a spring balance.

Blood cell morphology and leukocyte differential count determination

Blood cell morphology was determined in all the blood smears ($n = 320$). Cells evaluated were erythrocytes, leukocytes and thrombocytes. Cellular and nuclear morphology and size were determined on photographs taken with a color digital camera (Sony Dsc-W110) from the blood smears that were observed on a microscope (Maico® BM7-B) at 100x with immersion oil. Photographs were analyzed using the Motic Image Plus 3.0® software.

In two of the four blood smears from each animal ($n = 160$), leukocyte differential count was made using a manual leukocyte differential counter. The remaining two blood smears from each animal were stored as a reserve. Leukocytes were classified as heterophils, eosinophils, basophils, lymphocytes, monocytes and azurophils (Lovely et al., 2007; Stacy et al., 2011). One hundred leukocytes per slide were counted to determine the percentage of each cell type.

Statistical analysis

Descriptive statistics was used to determine the cellular length/diameter and the nuclear diameter for each type of blood cell; the results are presented as mean \pm standard deviation (SD). In the leukocyte differential count, descriptive statistics was used to determine the percentage of each cell type. Additionally, normality of the leukocyte differential data was evaluated with the Kolmogorov-Smirnov test. Since the data were normally distributed ($p = 0.10 - 0.20$), the Student's t-test was used to analyze differences in the percentage of each leukocyte type between subadults and adults, females and males, in the non-breeding and breeding seasons. Statistical significance was set at $p < 0.05$. The statistical software used was Statistica 10® (StatSoft®, Inc. USA).

RESULTS

The length/diameter of each peripheral blood cell type, as well as the diameter of their nucleus, were similar in subadult and adult crocodiles, males and females, in both seasons. Hence, data from both sizes and sexes were combined and an average was obtained for each cell type. In general, erythrocytes were the largest blood cells in Morelet's crocodile, while lymphocytes were the smallest. Among leukocytes, eosinophils were the largest. The morphological characteristics of the peripheral blood cells evaluated are described in Table 1 and shown in Figure 1 (a – h).

Regarding the leukocyte differential, in the general population of crocodiles, lymphocytes were the most abundant, followed by heterophils and azurophils, while basophils were the least numerous (Table 2).

Table 2. Leukocyte differential count (%) in farmed Morelet's crocodiles (*Crocodylus moreletii*).

	Mean ± SD	Range
Lymphocytes	36.6 ± 11.8	15 – 77
Heterophils	35.9 ± 9.1	15 – 59
Eosinophils	8.0 ± 6.3	0 – 23
Basophils	0.7 ± 1.6	0 – 5
Monocytes	5.9 ± 3.4	0 – 15
Azurophils	12.6 ± 5.7	1 – 33

When the size of the crocodiles was considered, lymphocytes were the most numerous in subadults and lymphocytes and heterophils in adults, while basophils were the least numerous in both sizes (Table 3). Subadult females had a lower percentage of heterophils in the non-breeding season

Table 1. Morphological characteristics of peripheral blood cells from healthy farmed Morelet's crocodiles (*Crocodylus moreletii*) subadults, adults, females and males.

Blood cell type	Shape and size	General characteristics
Erythrocytes		
Whole cell	Elliptical, large, 23.28 ± 3.96 µm length	Abundant pale blue cytoplasm.
Nucleus	Round to elliptical, 5.90 ± 1.14 µm diameter	Deeply basophilic, centrally positioned.
Leukocytes		
Lymphocytes		
Whole cell	Mostly round, small, 7.79 ± 1.51 µm diameter	Scant purple cytoplasm.
Nucleus	Irregular, large	Deeply purple with densely clumped chromatin, occupying most of the cell surface. Easily confounded with the cytoplasm, seeming that there was no nucleus.
Heterophils		
Whole cell	Round, 16.16 ± 2.40 µm diameter	Abundant medium purple cytoplasm filled with fine, dark purple granules.
Nucleus	Irregular, 6.80 ± 1.63 µm diameter	Eccentrically positioned; dark purple with dense chromatin.
Eosinophils		
Whole cell	Round, 17.30 ± 3.35 µm diameter	Dark purple cytoplasm with granules.
Nucleus	Round, 6.63 ± 1.70 µm diameter	Eccentric; dark purple with clumped chromatin.
Basophils		
Whole cell	Round, 11.44 ± 1.94 µm diameter	Dark purple cytoplasm with numerous small, round, dark purple granules that obscured the diameter of the nucleus, making it difficult to measure it.
Nucleus	N/E	Dark purple; centrally positioned and not easily distinguished from the cytoplasm.
Monocytes		
Whole cell	Almost round, 12.57 ± 3.11 µm diameter	Pale purple cytoplasm.
Nucleus	Reniform, large	Medium purple with slightly clumped chromatin.
Azurophils		
Whole cell	Almost round, 13.74 ± 1.64 µm diameter	Scant pale purple cytoplasm filled with fine, pale purple granules.
Nucleus	Round, 7.78 ± 1.33 µm diameter	Eccentric; dark purple with dense chromatin.
Thrombocytes		
Whole cell	Elliptical to oval, 9.81 ± 1.07 µm length	Scant, light purple cytoplasm that was obscured by the nucleus.
Nucleus	Round to oval; size not evaluated	Central; dark purple stained and occupying most of the cell surface. Commonly appeared in small clusters.

NE: not evaluated.

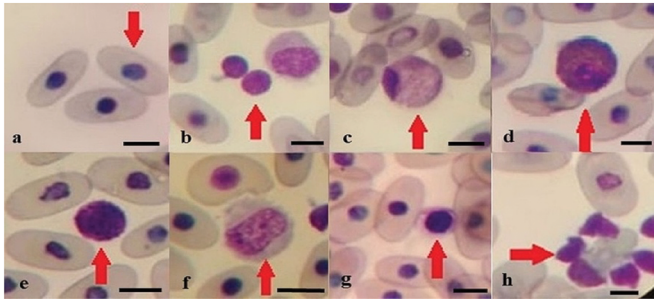


Figure 1. Morelet's crocodile (*Crocodylus moreletii*) peripheral blood cells stained with a Romanowsky-type staining, observed at 100x magnification. The arrows point to the indicated cell type. a) Erythrocyte. b) Lymphocyte. c) Heterophil. d) Eosinophil. e) Basophil. f) Monocyte. g) Azurophil. h) Thrombocyte. Bar = 10 μ m.

and a higher percentage of eosinophils and monocytes in the breeding season when compared to adult females ($p < 0.05$; Table 3). Likewise, subadult males had a higher percentage of lymphocytes and lower of heterophils in the non-breeding season and a higher percentage of azurophils in the breeding season when compared to adult males ($p < 0.05$; Table 3).

Regarding the sex of the crocodiles, lymphocytes were the most numerous in females and lymphocytes and heterophils in males, while basophils were the least numerous in both sexes (Table 3). No difference was found between female and male, subadult and adult individuals ($p > 0.05$; Table 3).

Concerning to the season of the year, lymphocytes and heterophils were the most abundant in the non-breeding season and lymphocytes in the breeding season; in both seasons basophils were the least numerous (Table 3). Subadult males had a higher percentage of lymphocytes and lower of eosinophils and azurophils in the non-breeding season ($p < 0.05$; Table 3). Adult males had a higher percentage of heterophils and lower of eosinophils and basophils in the non-breeding season ($p < 0.05$; Table 3). No difference was found between seasons in subadult and adult females ($p > 0.05$; Table 3).

DISCUSSION

Wildlife management requires the assessment of the health status of the individuals (Johnstone et al., 2012), both in captivity and in the wild. In higher vertebrates, health assessment and disease diagnosis require knowledge on the normal hematologic parameters, as they provide information particularly on the functioning of the immune system of individuals and populations (Stacy et al., 2011; Latorre et al., 2016). In crocodilians, hematologic parameters can also serve to evaluate their exposure to environmental contaminants or toxicants, which would make them potential indicators of ecosystem health (Milnes and Guillette, 2008; Latorre et al., 2016). That is the case for the American alligator, which is considered as an indicator

of wetland health throughout its distribution range (Milnes and Guillette, 2008).

In reptiles, routine hematologic evaluation includes assessment of blood cell morphology and leukocyte differential count, among other indicators (Stacy et al., 2011). Since blood cell morphology and count vary greatly among reptilians, it is necessary to know the normal characteristics and ranges for each species to detect sick individuals (Stacy et al., 2011; Mumm et al., 2019). Unlike several crocodilians in which the characteristics of their blood cells have been reported, there is no information available in the Morelet's crocodile, either captive or wild individuals. Thus, this study is the first to report the morphological characteristics of peripheral blood cells and the leukocyte differential of Morelet's crocodile females, males, subadults and adults in the non-breeding and breeding seasons.

Erythrocytes of Morelet's crocodile showed similar morphology to those from other crocodilians; however, they were larger than the erythrocytes from species such as American alligator (Glassman et al., 1981; Mateo et al., 1984), Broad-snouted and Yacare caiman (Moura et al., 1999; Barboza et al., 2007; Rossini and García, 2010; Zayas et al., 2011), Smooth-fronted caiman (*Paleosuchus trigonatus* Schneider, 1801) (Rojas, 2005), Spectacled caiman (Rossini, 2004; Rossini and García, 2010) and Chinese alligator (*Alligator sinensis* Fauvel, 1879) (Peng et al., 2018). These variations in erythrocyte size could result from differences between species, the size of the animals or the handling of the samples in each study (Stacy and Whitaker, 2000; Stacy et al., 2011).

In general, changes in the morphology and number of erythrocytes are indicative of pathological conditions, particularly anemia (Saggese, 2009). In reptiles, the presence of poikilocytosis (abnormality in erythrocyte morphology) can be normal in healthy animals; however, a high number of poikilocytes is associated with septicemia and severe chronic infection (Martínez-Silvestre, 2011). Also, diagnosis of anemia can help identify diseases before they become life-threatening conditions (Campbell and Ellis, 2007; Sykes and Klaphake, 2008).

Leukocytes of the Morelet's crocodile had similar morphology to those from the American alligator (Glassman et al., 1981), Yacare caiman (Oliveira et al., 1998; Moura et al., 1999), Siamese crocodile (*Crocodylus siamensis* Schneider, 1801) (Sakulwira et al., 2004) and Broad-snouted caiman (Zayas et al., 2011). However, their size showed some variations when compared to those from other crocodilians. Thus, in comparison with the Morelet's crocodile, the Broad-snouted caiman had larger lymphocytes, basophils and monocytes but smaller heterophils and eosinophils (Zayas et al., 2011); the American alligator had larger lymphocytes and smaller eosinophils (Glassman et al., 1981); and the Spectacled caiman had larger basophils and smaller heterophils and eosinophils (Rossini and García, 2010).

Table 3. Leukocyte differential count (% , mean \pm SD) in farmed Morelet's crocodiles (*Crocodylus moreletii*) females and males by season (non-breeding and breeding) and size (subadults and adults).

	Non-breeding season		Breeding season	
	Subadults	Adults	Subadults	Adults
Females				
Lymphocytes	39.5 \pm 11.5 ^{ac}	36.6 \pm 6.7 ^{Ac}	36.6 \pm 13.3 ^{aC}	45.1 \pm 17.7 ^{AC}
Heterophils	34.5 \pm 5.9 ^{ac}	40.2 \pm 5.9 ^{Ad}	30.3 \pm 6.3 ^{aC}	31.6 \pm 15.2 ^{AC}
Eosinophils	6.9 \pm 3.8 ^{ac}	4.6 \pm 1.8 ^{Ac}	11.6 \pm 5.6 ^{aC}	4.4 \pm 7.6 ^{AD}
Basophils	0.5 \pm 0.5 ^{ac}	0.0 \pm 0.0 ^{Ac}	1.1 \pm 1.0 ^{aC}	1.5 \pm 1.8 ^{AC}
Monocytes	5.9 \pm 2.7 ^{ac}	6.1 \pm 3.3 ^{Ac}	7.3 \pm 3.7 ^{aC}	3.0 \pm 3.9 ^{AD}
Azurophils	13.0 \pm 5.8 ^{ac}	12.5 \pm 4.9 ^{Ac}	13.1 \pm 4.7 ^{aC}	14.4 \pm 10.0 ^{AC}
Males				
Lymphocytes	41.4 \pm 11.7 ^{ac}	31.3 \pm 5.6 ^{Ad}	27.3 \pm 5.5 ^{bC}	37.7 \pm 14.9 ^{AC}
Heterophils	36.1 \pm 5.6 ^{ac}	42.9 \pm 6.3 ^{Ad}	36.8 \pm 8.3 ^{aC}	29.4 \pm 8.1 ^{BC}
Eosinophils	4.8 \pm 3.5 ^{ac}	4.9 \pm 3.0 ^{Ac}	12.5 \pm 7.5 ^{bC}	14.7 \pm 6.7 ^{BC}
Basophils	0.4 \pm 0.7 ^{ac}	0.0 \pm 0.0 ^{Ac}	0.7 \pm 0.7 ^{aC}	0.9 \pm 0.9 ^{BC}
Monocytes	5.7 \pm 4.0 ^{ac}	8.4 \pm 2.2 ^{Ac}	5.8 \pm 2.6 ^{aC}	5.9 \pm 3.3 ^{AC}
Azurophils	11.6 \pm 4.8 ^{ac}	12.5 \pm 3.6 ^{Ac}	16.9 \pm 3.6 ^{bC}	10.3 \pm 4.7 ^{AD}

^{a,b} Different superscript by row in subadult females and males indicates statistical difference by season ($p < 0.05$). ^{A,B} Different superscript by row in adult females and males indicates statistical difference by season ($p < 0.05$). ^{c,d} Different superscript by row in the non-breeding season in females and males indicates statistical difference by size ($p < 0.05$). ^{C,D} Different superscript by row in the breeding season in females and males indicates statistical difference by size ($p < 0.05$).

In the present study, a type of leukocyte that exhibited the same morphological characteristics as azurophils (Montali, 1988; Dotson et al., 1995; Alleman et al., 1999; Stacy et al., 2011) was observed in the peripheral blood of the Morelet's crocodile and therefore considered as such, separated from monocytes; this was also reported in the Nile crocodile (*Crocodylus niloticus* Laurenti, 1768) (Lovely et al., 2007). No other study was found that reported morphological characteristics or size of azurophils in other crocodilians. Only Moura et al. (1999) in the Yacare caiman mentioned the monocytes azurophils, with similar morphology to the azurophils from this study.

Of all leukocytes, eosinophils were the largest ones in the Morelet's crocodile, contrary to reports of heterophils being the largest leukocytes in the Yacare and Broad-snouted caiman (Mussart et al., 2006) and monocytes in the Broad-snouted caiman (Zayas et al., 2011). On the other hand, lymphocytes were the smallest blood cells in the Morelet's crocodile, like what was observed in the Yacare and Broad-snouted caiman (Mussart et al., 2006).

Thrombocytes of the Morelet's crocodile showed similar morphology to those from other crocodilians; likewise, they had a similar size to those from the American alligator (Glassman et al., 1981), but were smaller than thrombocytes from the Spectacled and Broad-snouted caiman (Rossini and García, 2010; Zayas et al., 2011).

Regarding the leukocyte differential, lymphocytes were the most numerous in the general population of Morelet's crocodile in this study, accounting for up to 77 % of

leukocytes. Similar results were reported in this same species (Padilla et al., 2011) and in Yacare and Broad-snouted caiman (Mussart et al., 2006; Zayas et al., 2011), all in captivity. In most reptiles, lymphocytes compose up to 80 % of leukocytes (Sypek and Borysenko, 1988; Divers et al., 1996; Troiano et al., 1997; Alleman et al., 1999; Lamirande et al., 1999), however, lymphocytes reached 95 % in farmed Nile crocodiles (Makinde and Alemu, 1991) and 85 % in wild Nile crocodiles (Lovely et al., 2007) but only 42 % in captive Orinoco crocodiles (*Crocodylus intermedius* Graves, 1819) (Manzanilla et al., 2011). These differences in lymphocyte percentages could be due to species-specific particularities, as these studies reported values from apparently healthy individuals.

In reptiles, an increase in lymphocytes is associated with inflammation, parasitic and viral infections, leukemia and wound cicatrization (Martínez-Silvestre et al., 2011). On the other hand, a decrease in lymphocytes is usually observed during winter, even in tropical regions (Alleman et al., 1999; Lamirande et al., 1999), and it is also associated with immunosuppression, stress and chronic malnutrition (Strik et al., 2007). Broad-snouted caimans exposed *in ovo* and *in vivo* to insecticides had decreased lymphocyte numbers (Latorre et al., 2016).

In this study, heterophils were the second most abundant leukocytes in the Morelet's crocodile, accounting for up to 59 %, similar to one result obtained previously in this same species (Padilla et al., 2011). Although the percentage of heterophils in reptiles varies within species, they constitute

more than 50 % of leukocytes in the peripheral blood (Mateo et al., 1984; Montali, 1988; Manzanilla et al., 2011). Nonetheless, heterophils only reached 20 % (Makinde and Alemu, 1991) and 39 % (Lovely et al., 2007) in farmed and wild Nile crocodiles, respectively, and 34 % in Broad-snouted caimans (Zayas et al., 2011), despite being the second most numerous leukocytes in these species. Unlike the present study, in the American alligator (Mateo et al., 1984; Schoeb et al., 2002), Mugger crocodile (*Crocodylus palustris* Lesson, 1831) (Stacy and Whitaker, 2000) and Orinoco crocodile (Manzanilla et al., 2011) heterophils were the predominant leukocytes.

Heterophils are phagocytic cells and the first to arrive at the site of infection (Strik et al., 2007; Martínez-Silvestre et al., 2011). Increases in the number of heterophils are associated with inflammation, infection, tissue damage, stress and neoplasias (Martínez-Silvestre et al., 2011). American alligators exposed to an organochlorine miticide/pesticide (Woodward et al., 1993) and young Broad-snouted caimans exposed to a glyphosate-based herbicide (Latorre et al. 2013) or to an insecticide *in ovo* and *in vivo* (Latorre et al., 2016) had increased heterophil counts. However, a physiological increase in heterophils results from the season of the year, with the highest numbers observed in the summer (Martínez-Silvestre et al., 2011). On the other hand, a decrease in the number of heterophils is associated with viral infections (Alleman et al., 1992).

Azurophils were the third most abundant leukocytes in Morelet's crocodiles in this study, constituting up to 33 %. This result was contrary to the 2 % obtained previously in this same species (Padilla et al., 2011). In Nile crocodiles, azurophils were also the third most abundant leukocyte, accounting for up to 21 % (Lovely et al., 2007). No other study considered azurophils as a leukocyte type in crocodilians. One reason for this could be that azurophils are sometimes considered as a type of monocyte and included in the monocyte count in the leukocyte differential (Tully and Mitchel, 2012). Thus, the result from the present study disagrees with information that indicates that azurophils are found in low percentages in reptiles other than snakes and that increased numbers frequently occur in chronic disease states (Stacy et al., 2011) or associated with inflammation and bacterial and parasitic infections (Martínez-Silvestre et al., 2011). The crocodiles from this study were apparently healthy, with no sign of chronic disease; therefore, azurophils may be normally more abundant in the Morelet's crocodile than in other crocodilians. These results also suggest that azurophils be considered separately from monocytes during the hematologic evaluation of crocodilians.

Eosinophils reached 23 % of leukocytes in the Morelet's crocodile. According to Stacy et al. (2011), eosinophils compose 7 % to 20 % of leukocytes in healthy reptiles and their circulating numbers vary with species and seasonal changes. This information agrees with the results obtained in the

Orinoco crocodile, with up to 14 % eosinophils (Manzanilla et al., 2011), and in the Nile crocodile, with up to 16 % (Lovely et al., 2007) and 8 % (Makinde and Alemu, 1991). Nonetheless, contrary results were reported previously in the Morelet's crocodile, with only 2.9 % eosinophils (Padilla et al., 2011), and in the Broad-snouted caiman, with up to 6 % (Zayas et al., 2011). Although eosinophil function in reptiles remains unclear, an abnormally high eosinophil percentage has been associated with antigenic stimulation, particularly endo- and ectoparasitism (Mead and Borysenko, 1984; Campbell, 2004). However, since the crocodiles from the present study were apparently healthy and dewormed before blood sampling, the slightly higher percentage of eosinophils observed in them with respect to the normal range in healthy reptiles might be normal in farmed Morelet's crocodile. On the other hand, a lower eosinophil count was observed in American alligators exposed to an organochlorine miticide/pesticide (Woodward et al., 1993).

Basophils accounted for up to 5 % of leukocytes in Morelet's crocodiles in this study. This result was similar to that obtained in Orinoco crocodiles (3.0 ± 2.1 %; Manzanilla et al., 2011) but lower than the result in Broad-snouted caimans (up to 10 %; Zayas et al., 2011), Nile crocodiles (up to 16 %; Lovely et al., 2007) and Morelet's crocodiles (18.6 %; Padilla et al., 2011). Nonetheless, all these results can be considered normal because the percentage of basophils ranges from 0 % to 40 % among reptile species (Sypek and Borysenko, 1988; Marks and Citino, 1990). An increase in the number of basophils is associated with intestinal parasites, hemoparasites and viral infections (Innis et al., 2007).

In this study, monocytes represented up to 15 % of total leukocytes in the Morelet's crocodile. It has been reported that monocytes usually compose 0 % to 10 % of leukocytes (Sypek and Borysenko, 1988; Campbell, 2004), which agrees with the results obtained in the Nile crocodile (Lovely et al., 2007), Morelet's crocodile (Padilla et al., 2011), Broad-snouted caiman (Zayas et al., 2011) and Orinoco crocodile (Manzanilla et al., 2011). However, in these two last species the percentage of monocytes included the cell type considered as azurophils in the present study. Broad-snouted caimans exposed *in ovo* and *in vivo* to insecticides had increased monocyte counts (Latorre et al., 2016). In general, increased numbers of monocytes are associated with inflammatory diseases (Strik et al., 2007).

All these results of the leukocyte differential indicate the existence of variations among crocodilian species, as has been mentioned by different authors. Nonetheless, besides these species-specific differences, the variations in the leukocyte differential could be attributed to diverse levels of antigenic stimulation within populations, i.e., differences between wild and captive animals could be due to the presence of parasites in wild animals and stress and husbandry in farmed individuals (Stacy and Whitaker,

2000; Stacy et al., 2011). In addition, factors such as the environment (particularly temperature and rainfall), geographical location, age, sex, genetic variations, breeding status, diet and sample handling make the results of reptile peripheral blood evaluation highly variable concerning cell morphology and concentration (Stacy et al., 2011; Zayas et al., 2011; Campbell, 2012). Therefore, to be considered significant, total and differential leukocyte count must differ from normal reference values at least twice as high or as low (Campbell, 2012). In reptiles, an increase in the leukocyte count has been observed in bacterial or parasitic infections, stress and exposure to toxicants from the environment (Woodward et al., 1993; Schoeb et al., 2002; Martínez-Silvestre et al., 2011).

Concerning the size of the crocodiles, the predominance of lymphocytes over the other leukocytes in subadult Morelet's crocodiles in this study agreed with what has been reported in subadult Nile crocodiles (Lovely et al., 2007); however, it differed from the result in captive subadult Muggger crocodiles, in which heterophils were the most numerous leukocytes (Stacy and Whitaker, 2000). On the other hand, basophils were the least abundant leukocytes in subadult individuals in this study; this was also observed in captive subadult Muggger crocodiles (Stacy and Whitaker, 2000); however, this result was different to that in subadult Nile crocodiles, in which monocytes were the least numerous (Lovely et al., 2007). In adult Morelet's crocodiles, heterophils and lymphocytes were the predominant leukocytes, as well as reported for captive adult Muggger crocodiles (Stacy and Whitaker, 2000). In the latter study, adult crocodiles had fewer lymphocytes than juveniles and subadults (Stacy and Whitaker, 2000).

Regarding the sex of the crocodiles, in this study lymphocytes were the most numerous leukocytes in females and both lymphocytes and heterophils in males. Similar results were obtained in captive Muggger crocodiles, as subadult females had more heterophils and lymphocytes than males, whereas adult females had more lymphocytes but fewer heterophils than males (Stacy and Whitaker, 2000). Under the same environmental conditions, females usually have more lymphocytes than their conspecific males of the same age (Sypek and Borysenko, 1988). In Nile crocodiles, the percentage of eosinophils was lower in males than in females, with no difference in the other leukocytes (Lovely et al., 2007). In Orinoco crocodiles, females had fewer basophils and more monocytes than males (Manzanilla et al., 2011).

Concerning the season of the year, there were differences in the percentage of some leukocytes in the non-breeding and breeding seasons in subadult and adult males. Male subadults had more lymphocytes and eosinophils but fewer azurophils in the non-breeding than in the breeding season. Male adults had more heterophils and eosinophils but fewer basophils in the non-breeding than in the breeding season.

As mentioned previously, the immune response in reptiles is highly influenced by the environment, particularly low temperature, which can suppress or inhibit such response (Martínez-Silvestre et al., 2011; Stacy et al., 2011).

Blood cell morphology and leukocyte differential of the Morelet's crocodile showed both similarities and differences regarding other crocodylians. However, a comparison of blood cell characteristics and leukocyte counts between different populations of Morelet's crocodile was not possible in this study because of the lack of data available on this species, despite its ecological and economic importance in its area of distribution. Therefore, this study contributes novel information towards the establishment of reference values for hematologic evaluation of Morelet's crocodiles. The data generated in this study can be used to diagnose specific diseases associated with abnormal blood cell morphology or increased or decreased leukocyte counts. Nonetheless, it is necessary to conduct more research in farmed and wild individuals to establish differences that may be due to the management of the animals, in order to make an accurate diagnosis of the health status of captive and wild populations. The diagnosis in the crocodiles of some blood disorders related to environmental contamination could also be used to assess the quality of the water used in farmed animals or the ecosystem health in the case of wild individuals.

CONCLUSIONS

The differences observed in blood cell morphology and leukocyte differential count between Morelet's crocodiles from this study and other crocodylians clearly indicate the need to have hematologic information on each species in order to establish specific reference values. Since the animals from this study were apparently healthy, the results obtained here could serve as reference for farmed and wild Morelet's crocodiles. More research is needed in Morelet's crocodile to complement these results in order to establish hematologic reference values for this species, both in the wild and under captivity, as well as to determine which factors might affect and modify the leukocyte differential in crocodylians.

ACKNOWLEDGMENT

Crocodile farm "El Colibrí de la Antigua, UMA Cacahuatal" for lending the animals for the study. The Mexican National Council of Science and Technology (CONACYT) for the doctorate scholarship granted to the first author.

CONFLICT OF INTEREST

The authors declare no conflict of interest.

REFERENCES

- Alleman, A. R., Jacobson, E. R., and Raskin, R. E. (1992). Morphologic and cytochemical characteristics of blood cells from the desert tortoise (*Gopherus agassizii*). *American Journal of Veterinary Research*, 53(9), 1645-1651.
- Alleman, A. R., Jacobson, E. R., and Raskin, R. E. (1999). Morphologic, cytochemical staining and ultrastructural characteristics of blood from eastern diamondback rattlesnakes (*Crotalus adamanteus*). *American Journal of Veterinary Research*, 60(4), 507-514.
- Barboza, N. N., Mussart, N. B., Coppo, J. A., Fioranelli, S. A., and Koza, G. A. (2007). Oscilaciones del eritrograma en caimanes criados por sistema ranching. *Revista Veterinaria*, 18(2), 84-91.
- Campbell, T. W. (2004). Hematology of reptiles. In M. A. Thrall (Ed.). *Veterinary Hematology and Clinical Chemistry* (pp. 259-276). Lippincott Williams and Wilkins.
- Campbell, T. W. (2012). Hematology of reptiles. In M. A. Thrall, G. Weiser, R. W. Allison, y T. W. Campbell (Ed.). *Veterinary Hematology and Clinical Chemistry* (pp. 277-297). Wiley-Blackwell.
- Campbell, T. W., and Ellis, C. K. (2007). Hematology of reptiles. En T. W. Campbell, and C. K. Ellis (Eds.). *Avian and Exotic Hematology and Cytology* (pp. 51-81). Blackwell Publishing.
- Canfield, P. J. (1985). Characterization of the blood cells of Australian crocodiles (*Crocodylus porosus* [Schneider] and *C. johnstoni* [Kreffft]). *Anatomia, Histologia, Embryologia*, 14(3), 269-288. <https://doi.org/10.1111/j.1439-0264.1985.tb00284.x>
- Cedeño-Vázquez, J. R., Platt, S. G., and Thorbjarnarson, J. (28 de junio de 2019). *IUCN Crocodile Specialist Group. Crocodylus moreletii*. The IUCN Red List of Threatened Species 2012; e.T5663A3045579. <https://doi.org/10.2305/IUCN.UK.2012.RLTS.T5663A3045579.en>
- Convention on International Trade in Endangered Species of Wild Fauna and Flora (CITES). (19 de diciembre de 2019). Convention on International Trade in Endangered Species of Wild Fauna and Flora. <https://www.cites.org/eng/disc/what.php>
- Divers, S. J., Redmayne, G., and Aves, E. K. (1996). Haematological and biochemical values of 10 green iguanas (*Iguana iguana*). *Veterinary Record*, 138(9), 203-205. <https://doi.org/10.1136/vr.138.9.203>
- Dotson, T. K., Ramsay, E. C., and Bounous, D. I. (1995). A color atlas of the blood cells of the yellow rat snake. *Compendium on Continuing Education for the Practising Veterinarian*, 17, 1013-1016.
- Glassman, A. B., Bennett, C. E., and Hazen, T. C. (1981). Peripheral blood components in *Alligator mississippiensis*. *Transactions of the American Microscopical Society*, 100(2), 210-215. <https://doi.org/10.2307/3225803>
- Innis, C. J., Tlusty, M., and Wunn, D. (2007). Hematologic and plasma biochemical analysis of juvenile head-started northern red-bellied cooters (*Pseudemys rubriventris*). *Journal of Zoo and Wildlife Medicine*, 38(3), 425-432. [https://doi.org/10.1638/1042-7260\(2007\)38\[425:HAPBAO\]2.0.CO;2](https://doi.org/10.1638/1042-7260(2007)38[425:HAPBAO]2.0.CO;2)
- International Union for Conservation of Nature (IUCN). (11 de febrero de 2020). Red List of Threatened Species: *Crocodylus moreletii*; 2012. <https://www.iucnredlist.org/species/5663/3045579>
- Johnstone, C. P., Reina, R. D., and Lill, A. (2012). Interpreting indices of physiological stress in free-living vertebrates. *Journal of Comparative Physiology B*, 182(7), 861-879. <https://doi.org/10.1007/s00360-012-0656-9>
- Lamirande, E. W., Bratthauer, A. D., Fisher, D. C., and Nichols, D. K. (1999). Reference hematologic and plasma chemistry values of brown tree snakes (*Boiga irregularis*). *Journal of Zoo and Wildlife Medicine*, 30(4), 516-520.
- Latorre, M. A., López González, E. C., Larriera, A., Poletta, G. L., and Siroski, P. A. (2013). Effects of *in vivo* exposure to Roundup® on immune system of *Caiman latirostris*. *Journal of Immunotoxicology*, 10(4), 349-354. <https://doi.org/10.3109/1547691X.2012.747233>
- Latorre, M. A., Romito, M. L., Larriera, A., Poletta, G. L., and Siroski, P. A. (2016). Total and differential white blood cell counts in *Caiman latirostris* after *in ovo* and *in vivo* exposure to insecticides. *Journal of Immunotoxicology*, 13(6), 903-908. <https://doi.org/10.1080/1547691X.2016.1236854>
- Lovely, C. J., Pittman, J. M., and Leslie, A. J. (2007). Normal haematology and blood biochemistry of wild Nile crocodiles (*Crocodylus niloticus*) in the Okavango Delta, Botswana. *Journal of the South African Veterinary Association*, 78(3), 137-144. <https://doi.org/10.4102/jsava.v78i3.305>
- Makinde, M. O., and Alemu, P. (1991). Erythrocyte membrane osmotic fragility and some haematological values of captive Nile crocodiles (*Crocodylus niloticus*). *Zimbabwe Veterinary Journal*, 22, 119-125.
- Manzanilla, F. A. G., Seijas, A. E., and Rossini, M. (2011). Valores hematológicos en ejemplares jóvenes de caimán del Orinoco (*Crocodylus intermedius*) en Venezuela. *Revista Científica de la Facultad de Ciencias Veterinarias*, XXI(4), 360-364.
- Marks, S. K., and Citino, S. B. (1990). Hematology and serum chemistry of the radiated tortoise (*Testudo radiata*). *Journal of Zoo and Wildlife Medicine*, 21(3), 342-344.
- Martínez-Silvestre, A., Lavín, S., and Cuenca, R. (2011). Hematología y citología sanguínea en reptiles. *Clínica Veterinaria de Pequeños Animales*, 31(3), 131-141.
- Mateo, M. R., Roberts, E. D., and Enright, F. M. (1984). Morphologic, cytochemical and functional studies of peripheral blood cells of young healthy American alligators (*Alligator mississippiensis*). *American Journal of Veterinary Research*, 45(5), 1046-1053.

- Mead, K. F., and Borysenko, M. (1984). Surface immunoglobulin on granular and agranular leukocytes in the thymus and spleen of the snapping turtle, *Chelydraserpentina*. *Developmental & Comparative Immunology*, 8(1), 109-120. [https://doi.org/10.1016/0145-305X\(84\)90015-6](https://doi.org/10.1016/0145-305X(84)90015-6)
- Milnes, M. R., and Guillette Jr., L. J. (2008). Alligator tales: new lessons about environmental contaminants from a sentinel species. *Bioscience*, 58(11), 1027-1036. <https://doi.org/10.1641/B581106>
- Montali, R. J. (1988). Comparative pathology of inflammation in the higher vertebrates (reptiles, birds and mammals). *Journal of Comparative Pathology*, 99(1), 1-26. [https://doi.org/10.1016/0021-9975\(88\)90101-6](https://doi.org/10.1016/0021-9975(88)90101-6)
- Moura, W. L., Matushima, E. R., Oliveira, L. W., and Egami, M. I. (1999). Morphological and cytochemical observations of blood cells of *Caiman crocodilus yacare* (Daudin, 1802) (Reptilia, Crocodylia). *Brazilian Journal of Veterinary Research and Animal Science*, 36(1), 45-50. <https://doi.org/10.1590/S1413-95961999000100009>
- Mumm, L. E., Winter, J. M., Andersson, K. E., Glowacki, G. A., Adamovicz, L. A., and Allender, M. C. (2019). Hematology and plasma biochemistries in the Blanding's turtle (*Emydoidea blandingii*) in Lake County, Illinois. *PLOS ONE*, 14(11), e0225130. <https://doi.org/10.1371/journal.pone.0225130>
- Mussart, N. B., Barboza, N. N., Fioranelli, S. A., Koza, G. A., Prado, W. S., and Coppo, J. A. Age, sex, year season, and handling system modify the leukocytal parameters from captive *Caiman latirostris* and *Caiman yacare* (Crocodylia: Alligatoridae). *Revista Veterinaria*, 17(1), 3-10.
- Oliveira, L. W., Moura, W. L., Matushima, E. R., and Egami, M. I. (1998). Características citoquímicas morfológicas y ultraestructurales de eosinófilos de *Caiman crocodilus yacare* (Daudin, 1802) (Reptilia, Crocodylia). *Revista chilena de anatomía*, 16(2), 245-254. <https://doi.org/10.4067/S0716-98681998000200012>
- Padilla, S. E., Weber, M., and Jacobson, E. R. (2011). Hematologic and plasma biochemical reference intervals for Morelet's crocodiles (*Crocodylus moreletii*) in the northern wetlands of Campeche, Mexico. *Journal of Wildlife Diseases*, 47(3), 511-522. <https://doi.org/10.7589/0090-3558-47.3.511>
- Peng, F., Chen, X., Meng, T., Li, E., Zhou, Y., and Zhang, S. (2018). Hematology and serum biochemistry parameters of captive Chinese alligators (*Alligator sinensis*) during the active and hibernating periods. *Tissue and Cell*, 51, 8-13. <https://doi.org/10.1016/j.tice.2018.02.002>
- Platt, S. G., and Thorbjarnarson, J. B. (2000). Population status and conservation of Morelet's crocodile, *Crocodylus moreletii*, in northern Belize. *Biological Conservation*, 96(1), 21-29. [https://doi.org/10.1016/S0006-3207\(00\)00039-2](https://doi.org/10.1016/S0006-3207(00)00039-2)
- Rojas, M. G. (2005). *Caracterización morfológica de células sanguíneas del caimán de frente lisa (Paleosuchus trigonatus, Schneider 1801) mantenidos en cautiverio en Perú*. Proceedings de la Reunión Regional de América Latina y el Caribe del Grupo de Especialistas en Cocodrilos IUCN.
- Rossini, V. M. (2004). *Determinación de los parámetros hematológicos de la baba (Caiman crocodilus) en hábitat silvestre*. Anales del XIX Congreso Panamericano de Ciencias Veterinarias.
- Rossini, V. M., and García, C. G. (2010). Descripción morfológica de las células sanguíneas de la Baba (*Caiman crocodilus crocodilus*) en vida silvestre. *Revista de la Facultad de Ciencias Veterinarias*, 51(2), 63-70.
- Saggese, M. D. (2009). Clinical approach to the anemic reptile. *Journal of Exotic Pet Medicine*, 18(2), 98-111. <https://doi.org/10.1053/j.jepm.2009.04.003>
- Sakulwira, K., Klomklew, W., Vethchagarun, S., and Pothiwong, W. (2004). The structure of red blood cells, white blood cells and thrombocytes in freshwater crocodiles (*Crocodylus siamensis*). *The Thai Journal of Veterinary Medicine*, 34(1), 83-90.
- Sánchez-Herrera, O., López, S. G., García, O. H. A., and Benítez, D. H. (2011). *Programa de monitoreo del Cocodrilo de pantano (Crocodylus moreletii) México-Belice-Guatemala*. Comisión Nacional para el Conocimiento y Uso de la Biodiversidad (CONABIO). <https://doi.org/10.5962/bhl.title.116577>
- Schoeb, T. R., Heaton-Jones, T. G., Clemmons, R. M., Carbonneau, D. A., Woodward, A. R., Shelton, D., Poppenga, R. H. (2002). Clinical and necropsy findings associated with increased mortality among American alligators of Lake Griffin, Florida. *Journal of Wildlife Diseases*, 38(2), 320-337. <https://doi.org/10.7589/0090-3558-38.2.320>
- Secretaría de Medio Ambiente y Recursos Naturales (SEMARNAT). (18 de diciembre de 2019). *Norma Oficial Mexicana NOM-059-SEMARNAT-2010, Protección ambiental-Especies nativas de México de flora y fauna silvestres-Categorías de riesgo y especificaciones para su inclusión, exclusión o cambio-Lista de especies en riesgo; 2010*. <http://biblioteca.semarnat.gob.mx/janium/Documentos/Ciga/agenda/DOFsr/DO2454.pdf>
- Somaweera, R., Nifong, J., Rosenblatt, A., Brien, M. L., Combrink, X., Else, R. M., Grigg, G., Magnusson, W. E., Mazzotti, F. J., Percy, A., Platt, S. G., Shirley, M. H., Tellez, M., Ploeg, J. v. d., Webb, G., Whitaker, R., and Webber, B. L. (2020). The ecological importance of crocodylians: towards evidence-based justification for their conservation. *Biological Reviews*, 95(4), 936-959. <https://doi.org/10.1111/brv.12594>
- Stacy, B. A., and Whitaker, N. (2000). Hematology and blood biochemistry of captive Mugger crocodiles (*Crocodylus palustris*). *Journal of Zoo and Wildlife Medicine*, 31(3), 339-347. [https://doi.org/10.1638/1042-7260\(2000\)031\[0339:HABBOC\]2.0.CO;2](https://doi.org/10.1638/1042-7260(2000)031[0339:HABBOC]2.0.CO;2)

- Stacy, N. I., Alleman, A. R., and Sayler, K. A. (2011). Diagnostic hematology of reptiles. *Clinics in Laboratory Medicine*, 31(1), 87-108. <https://doi.org/10.1016/j.cll.2010.10.006>
- Strik, N. I., Alleman, A. R., and Harr, K. E. (2007). Circulating inflammatory cells. In E. R. Jacobson (Ed.). *Infectious Diseases and Pathology of Reptiles: Color Atlas and Text* (pp. 167-218). CRC Press.
- Sykes, J. M., and Klaphake, E. (2008). Reptile hematology. *Veterinary Clinics of North America: Exotic Animal Practice*, 11(3), 481-500. <https://doi.org/10.1016/j.cvex.2008.03.005>
- Sypek, J., and Borysenko, M. (1988). Reptiles. In A. F. Rowley, and N. A. Ratcliffe (Ed.) *Vertebrate Blood Cells* (pp. 211-256). Cambridge University Press.
- Troiano, J. C., Vidal, J. C., Gould, J., and Gould, E. (1997). Haematological reference intervals of the South American rattlesnake (*Crotalus durissus terrificus*, Laurenti, 1768) in captivity. *Comparative Haematology International volume*, 7, 109-112. <https://doi.org/10.1007/BF02652577>
- Tully, T. N., and Mitchell, M. A. (2012). *A veterinary technician's guide to exotic animal care* (2 ed). AAHA Press.
- Woodward, A. R., Jennings, M. L., Percival, H. F., and Moore, C. T. (1993). Low clutch viability of American alligators on Lake Apopka. *Florida Scientist*, 56(1), 52-63.
- Zayas, M. A., Rodríguez, H. A., Galoppo, G. H., Stoker, C., Durando, M., Luque, E. H., Muñoz-de-Toro, M. (2011). Hematology and blood biochemistry of young healthy Broad-snouted caimans (*Caiman latirostris*). *Journal of Herpetology*, 45(4), 516-524. <https://doi.org/10.1670/10-158.1>