Acute interstitial nephritis secondary to atheroembolic renal disease as a mimic of ANCA vasculitis

Simón Hoyos-Patiño, Ana María Valencia-Ruíz, Luis F. Arias†, John Fredy Nieto-Ríos • Medellín (Colombia)

DOI: https://doi.org/10.36104/amc.2024.3677

Abstract

Atheroembolic renal disease is an uncommon cause of acute kidney injury (AKI) caused by renal artery occlusion due to cholesterol crystals. It is multisystemic, affecting the kidneys, skin, gastrointestinal system and brain. In some cases, it can mimic anti-neutrophilic cytoplasmic antibody (ANCA) vasculitis due to the presence of these autoantibodies.

We present the case of a 66-year-old man with cardiovascular risk factors and chronic kidney disease who suffered kidney function deterioration one month after abdominal aortic aneurysm repair with an endovascular graft. On physical exam, he had violaceous discoloration of the toes and livedo reticularis. Tests showed the presence of ANCA and peripheral eosinophilia. A kidney biopsy confirmed acute interstitial nephritis, which supported the diagnosis of atheroembolic renal disease. Steroid treatment improved his kidney function, with a favorable outcome.

This case underlines the importance of differentiating atheroembolic renal disease from ANCA-associated vasculitides through a careful differential diagnosis. **(Acta Med Colomb 2024; 49. DOI: https://doi.org/10.36104/amc.2024.3677).**

Keywords: *vasculitis mimic, acute kidney injury, ANCA, atheroembolic renal disease*

Dr. Simón Hoyos-Patiño: Departamento de Medicina Interna, Facultad de Medicina, Universidad Pontificia Bolivariana; Dra. Ana María Valencia-Ruíz: Departamento de Medicina Interna, Hospital Pablo Tobón Uribe; Dr. Luis F. Arias†: Departamento de Patología, Facultad de Medicina, Universidad de Antioquia; Dr. John Fredy Nieto-Ríos: Departamento de Nefrología y Trasplante Renal Hospital Pablo Tobón Uribe. Departamento de Medicina Interna, Facultad de Medicina, Universidad de Antioquia. Medellín (Colombia).
Correspondencia: Dr. Simón Hoyos Patiño. Medellín (Colombia).
E-Mail: simon23h@hotmail.com
Received: 21/VIII/2024 Accepted: 16/IX/2024

Introduction

Atheroembolic renal disease is one cause of acute kidney injury (AKI) and acute kidney disease (AKD), secondary to the occlusion of arteries, arterioles and renal glomerular capillaries by cholesterol crystals derived from atheromatous plaques in the aorta and its main branches (1). This material can be dislodged following an intravascular procedure or with anticoagulation (2). Atheroemboli typically affect the kidneys, skin, gastrointestinal system and brain, and therefore are considered to be a multisystemic disease (3).

This syndrome is one of the small vessel vasculitis mimickers (4), as it can cause livedo reticularis, purpura, nodules, blue finger syndrome, ischemia, AKI and uncontrolled hypertension (HTN), as well as constitutional symptoms and elevated inflammatory markers (5, 6). Laboratory tests show anemia, thrombocytopenia, eosinophilia, elevated C-reactive protein (CRP) and erythrocyte sedimentation rate (ESR), proteinuria and eosinophiluria (5, 6). Positive antineutrophil cytoplasmic antibodies (ANCAs) have also been reported, which makes the differential diagnosis even more difficult (7, 8).

We present the case of a man who debuted with AKD, blue finger syndrome, peripheral eosinophilia and refractory HTN due to acute interstitial nephritis secondary to a renal atheroembolism with positive ANCAs as a small vessel vasculitis mimicker.

Case description

We present the case of a 66-year-old man with a history of smoking, HTN, prediabetes, obesity, knee osteoarthritis, dyslipidemia, nonobstructive nephrolithiasis, and stage 3aAx chronic kidney disease (CKD), with a baseline creatinine of 1.5 mg/dL and an estimated glomerular filtration rate (eGFR) using the CKD-EPI formula of 48 mL/min/1.73 m^2. He also had an infrarenal abdominal aortic aneurysm with progressive growth to more than 5 cm in diameter. Therefore, in January 2023, he underwent aneurysm correction with a stent graft, during which complex aortic atheromatosis was found. He was treated comprehensively with aspirin, clopidogrel, atorvastatin, losartan, empagliflozin and acetaminophen.

One month later, he was hospitalized at Hospital Pablo Tobón Uribe due to accelerated deterioration of his kidney function found on ambulatory visits over the previous four weeks: an initial creatinine of 1.5 mg/dL, progressively rising to 4.5 mg/dL on hospital admission. On admission, his

blood pressure was 170/100 mmHg, and the rest of his vital signs were within normal limits. In a review of systems, he reported a 10 kg unintentional weight loss over the previous month, asthenia, weakness, hyporexia, choluria and nocturia. On physical exam, he had a purple tinge on the soles and pads of the toes of both feet, along with livedo reticularis (Figure 1). An Acute Disease Quality Initiative (ADQI 3) AKD diagnosis was explored. Possible pre and post-renal etiologies were ruled out, and it was therefore considered to be intrinsic (parenchymal) AKD.

A renal ultrasound showed normal-sized kidneys with no structural abnormalities. A urinalysis reported a density of 1.010, proteins at 75 mg/dL, and sediment with 10 leukocytes per high-power field, with no bacteria. Complementary lab tests (Table 1) were remarkable for the significant positivity of ANCAs measured by ELISA, both myeloperoxidase (MPO) and proteinase 3 (PR3), along with peripheral eosinophilia. Due to the diagnostic uncertainty between tubulointerstitial nephritis (TIN) and the possibility of rapidly progressive glomerulonephritis (RPGN), a kidney biopsy was taken, which confirmed TIN with associated acute tubular damage, and ruled out RPGN (Figure 2). Within the clinical context, this finding was interpreted as secondary to a renal atheroembolism, which explained the positive ANCAs, peripheral eosinophilia, cutaneous findings and TIN. The cholesterol emboli could not be found in the sample examined.

The patient was treated with methylprednisolone pulses followed by oral prednisolone for six weeks, with which his kidney function partially improved without the need for dialysis, with a final follow-up creatinine of 2.7 mg/dL (in February 2024).

Discussion

Atheroembolic renal disease occurs in patients with systemic atherosclerosis and cardiovascular risk factors (1). An incidence of 1.1-4.5% (9) has been reported, and it is estimated to account for 5-10% of AKI cases (10). Aortic atherosclerosis must exist for this condition to develop, and this occurs when there is acute stress leading to the rupture of atherosclerotic plaque releasing the inflammatory core. This is mainly iatrogenic, associated with vascular procedures, anticoagulation or thrombolysis (3).

Once in the bloodstream, cholesterol microcrystals obstruct the arterial microcirculation and cause endothelial inflammation with neutrophilic, eosinophilic, and mononuclear infiltration and the formation of giant cells; this triggers microthromboses and arterial obstruction that leads to ischemia (11). Histologically, cholesterol crystals can be found in the lumen of arcuate and interlobular arteries, with ischemic glomerular and interstitial changes (1). Kidney function may be acutely, subacutely or chronically affected (12). The acute form generally occurs one week after the causal event and is associated with gastrointestinal and cutaneous involvement (1). The kidney prognosis varies;

Figure 1. *Purplish toes and distal plantar area of both feet.*

Table 1. *Laboratory tests on admission.*

Laboratory test	Result	Reference value
Hgb	11.7 g/dL	13-17 g/dL
ESR	87 mm/h	0-20 mm/h
Leukocytes	12,550 mm^3	4,500-10,000 mm^3
Eosinophils	1,283 mm^3	0-1,500 mm^3
Creatinine	4.5 mg/dL	0.6-1.1 mg/dL
Urea nitrogen	88 mg/dL	8.4 – 25.7 mg/dL
Urinalysis	Density 1.010 75 mg/dL of protein 10 leukocytes per HPF 5 erythrocytes per HPF	No protein, 2 erythrocytes per HPF, 5 leukocytes per HPF
ANA	Negative	Negative
Anti-Ro antibodies	3.5 U	0-20 U
Anti-La antibodies	8.2 U	0-20U
Anti-Sm antibodies	3.8 U	0-20 U
Anti-RNP antibodies	2.6 U	0-20 U
C3	118 mg/dL	82-185 mg/dL
C4	45 mg/dL	15-53 mg/dL
Anticardiolipin IgG	17.85 GPL units	0-15 GPL U
Anticardiolipin IgM	5.11 MPL units	0-12.5 MPL U
B2GP IgG	2.91 U	0-20 U
B2GP IgM	11.56 U	0-20 U
Lupus anticoagulant	Negative	1.2 seconds (negative)
MPO-ANCAs	33 U/L	0-20 U/L
PR3-ANCAs	69.7 U/L	0-20 U/L
Protein electrophoresis	Normal	Normal
Immunoglobulin count	Normal	Normal
HIV, VDRL, hepatitis B, hepatitis C	Negative	Negative

Hgb: hemoglobin, ESR: erythrocyte sedimentation rate, HPF: high-power field, ANA: antinuclear antibodies, ENA: extractable nuclear antigen antibodies, C3: C3 complement fraction, C4: C4 complement fraction, IgG: immunoglobulin G, IgM: immunoglobulin M, B2GP: beta 2 glycoprotein, MPO-ANCAs: antimyeloperoxidase antineutrophil cytoplasmic antibodies, PR3-ANCAs: antiproteinase 3 antineutrophil cytoplasmic antibodies, HIV: human immunodeficiency virus, VDRL: Venereal Disease Research Laboratory. U: units

28-61% of acute and subacute patients require dialysis, with recovery in 20-30% of cases (1).

Cutaneous involvement is the most common extrarenal manifestation, in up to 88% of cases (13). The lesions typically include foot cyanosis with pain and coolness to touch, which may progress to ulcers, gangrene and amputation, along with livedo reticularis (1). There may also be fever, weight loss, myalgia, and headache, reflecting systemic involvement (3, 10, 11). Laboratory findings include anemia, leukocytosis, thrombocytopenia and elevated CRP and ESR, along with eosinophilia, which may be found in up to 80% of cases, helping to establish the diagnosis (1, 14). All of these signs and symptoms and laboratory findings, together with the acute-subacute kidney function deterioration, make renal atheroembolic disease a mimic of small vessel vasculitis (2, 4) considering that it can present with positive ANCAs (7, 8, 12, 15). ANCAs are essential for diagnosing systemic small vessel vasculitides (16); however, they are not specific and may occur in other pathologies like infections, ulcerative colitis, systemic lupus erythematosus, rheumatoid arthritis, drug use, poisons and renal atheroembolism (4, 7, 8, 16, 17).

In the patient we have presented, the acute-subacute kidney function deterioration, along with weight loss, eosinophilia, purplish feet and positive ANCAs suggested small vessel vasculitis. However, the kidney biopsy ruled out this diagnosis and, together with the clinical picture and history of abdominal aortic aneurysm repair, established the diagnosis of renal atheroembolic disease with associated TIN and acute tubular damage.

The literature reports few cases of renal atheroembolism as an imitator of ANCA vasculitis. Sugimoto T et al. reported the case of a 75-year-old man who developed cholesterol embolism syndrome after coronary bypass, with palpable purpura, purplish feet, eosinophilia, AKI that required renal replacement therapy (RRT), and positive MPO-ANCAs that improved with steroids (18). This resembled the case we have reported in its signs and

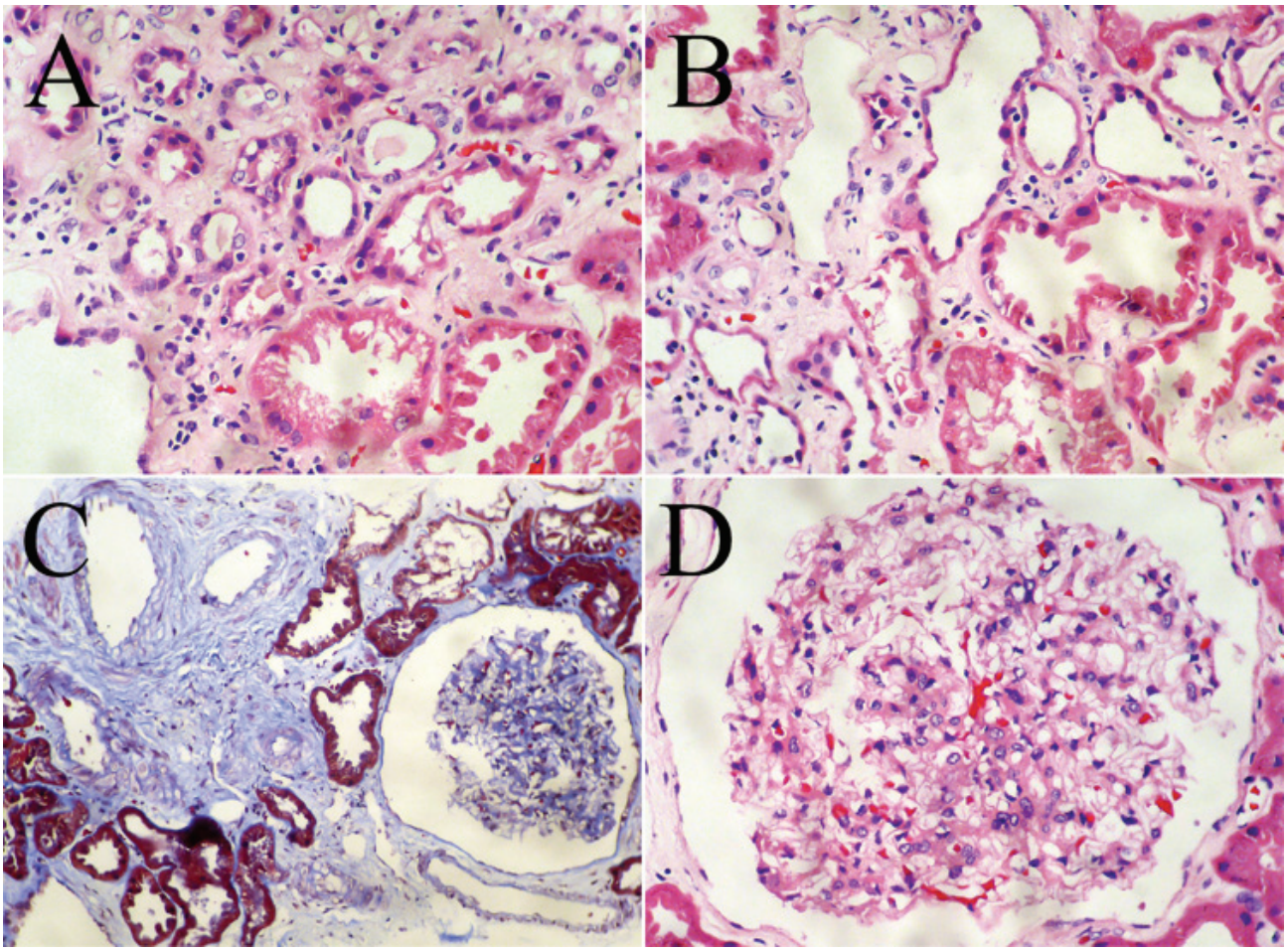

Figure 2. **A***: interstitium showing edema; there is mononuclear inflammatory infiltrate with diffuse lymphocytes and lymphocyte exocytosis to the tubular epithelium. Hematoxylin-eosin, original magnification, X400.* **B***: This picture shows a greater degree of tubular damage, with lumen dilation, cellular flattening and sloughing of some epithelial cells; there are diffuse lymphocytes in the interstitium. Hematoxylin-eosin, original magnifiaction, X400.* **C***: This picture shows a large glomerulus, with ample Bowman's space, without hypercellularity. Several small caliber arteries, with no cholesterol emboli in the biopsied arteries. Masson's trichrome, original magnification, X200.* **D***: Although the glomeruli are enlarged (glomerulomegaly) they do not have specific abnormalities, the immunofluorescence is negative, and the podocytes and basal membranes had normal characteristics. Hematoxylin-eosin, original magnification, X400.*

symptoms, history of arterial manipulation, eosinophilia and positive ANCAs.

Zhang J et al. (8) published the case of a 69-year-old man who developed cholesterol embolism syndrome spontaneously secondary to atherosclerosis of the femoral and popliteal arteries. This patient presented with foot cyanosis, necrosis and gangrene, AKI requiring RRT, refractory HTN, elevated inflammatory markers, eosinophilia and PR3-ANCAs which improved with steroids, cyclophosphamide, aspirin, atorvastatin, clopidogrel and cilostazol. This case is similar to ours as far as signs and symptoms, laboratory findings and the presence of anti-PRS, mimicking ANCA vasculitis. It differs in the lack of arterial manipulation, the need for RRT and treatment with immunosuppressants.

Maeshima E, et al (19) described the case of a 50-year-old man who developed a fever, HTN, AKI, ulcers on both feet, elevated inflammatory markers and positive PR3 and MPO ANCAs following cardiac catheterization and thoracic aortic aneurysm repair. His final diagnosis was cholesterol embolism syndrome, arrived at through a skin biopsy, which improved with steroids and cyclophosphamide. This report resembles ours in the history of arterial interventionism, the clinical picture and positive PR3 and MPO ANCAs.

In our case, the acute kidney function deterioration, HTN, elevated inflammatory reactants and purplish feet, together with positive ANCAs, led to an initial suspicion of small vessel vasculitis. However, the biopsy, which did show these findings, along with signs of interstitial nephritis and the clinical picture and history of abdominal aortic aneurysm repair, led to the diagnosis of renal atheroembolic disease mimicking ANCA vasculitis. The patient's kidney function was stabilized with supportive medical management, control of cardiovascular risk factors, steroids and restriction of nephrotoxic substances, without the need for dialysis, and the patient ended up with stage 4 kidney disease.

References

1. **Scolari F, Ravani P.** Atheroembolic renal disease. *The Lancet*. 2010;375(9726):1650-60. doi: 10.1016/S0140-6736(09)62073-0.
2. **Vassalotti JA, Delgado FA, Whelton A.** Atheroembolic renal disease. *American Journal of Therapeutics*. 1996;3(7):544.
3. **Fine MJ, Kapoor W, Falanga V.** Cholesterol Crystal Embolization: A Review of 221 Cases in the English Literature. *Angiology*. 1987;38(10):769-84. doi: 10.1177/000331978703801007.
4. **Maningding E, Kermani TA.** Mimics of vasculitis. *Rheumatology*. 2021;60(1):34-47. doi: 10.1093/rheumatology/keaa495.
5. **Ozkok A.** Cholesterol-embolization syndrome: current perspectives. *Vasc Health Risk Manag*. 2019;15:209-20. doi: 10.2147/VHRM.S175150.
6. **Firas G, Deepthi V, Jagadeesh K, Sridevi D, Noah T, Prem S, et al.** Cholesterol crystal embolization following plaque rupture: a systemic disease with unusual features. *J Biomed Res*. 2017;31(2):82-94. doi: 10.7555/JBR.31.20160100
7. **Kojima R, Harada M, Yamaguchi A, Hashimoto K, Kamijo Y.** Cholesterol Emboli Co-Existing with Anti-Neutrophil Cytoplasmic Antibody-Associated Vasculitis in a 76-Year-Old Woman. *Tohoku J Exp Med*. 2020;251(1):61-8. doi: 10.1620/tjem.251.61.
8. **Zhang J, Zhang HY, Chen SZ, Huang JY.** Anti-neutrophil cytoplasmic antibodies in cholesterol embolism: A case report and literature review. *Experimental and Therapeutic Medicine*. 2016;12(2):1012-8. doi: 10.3892/etm.2016.3349
9. **Mittal BV, Alexander MP, Rennke HG, Singh AK.** Atheroembolic renal disease: A silent masquerader. *Kidney International*. 2008;73(1):126-30. doi: 10.1038/sj.ki.5002433
10. **Mayo RR, Swartz RD.** Redefining the incidence of clinically detectable atheroembolism. *The American Journal of Medicine*. 1996;100(5):524-9. doi: 10.1016/s0002-9343(95)00059-3.
11. **Jones DB, Iannaccone PM.** Atheromatous emboli in renal biopsies. An ultrastructural study. Am J Pathol. 1975;78(2):261-76.
12. **Meyrier A.** Cholesterol crystal embolism: Diagnosis and treatment. Kidney International. 2006;69(8):1308-12. doi: 10.1038/sj.ki.5000263
13. **Jucgla A, Moreso F, Muniesa C, Moreno A, Vidaller A.** Cholesterol embolism: Still an unrecognized entity with a high mortality rate. *Journal of the American Academy of Dermatology*. 2006;55(5):786-93. doi: 10.1016/j.jaad.2006.05.012. Epub 2006 Jun 27.
14. **Kasinath BS, Corwin HL, Bidani AK, Korbet SM, Schwartz MM, Lewis EJ.** Eosinophilia in the Diagnosis of Atheroembolic Renal Disease. Am J Nephrol. 1987;7(3):173-7. doi: 10.1159/000167459.
15. **Scolari F, Tardanico R, Zani R, Pola A, Viola BF, Movilli E, et al.** Cholesterol crystal embolism: A recognizable cause of renal disease. *American Journal of Kidney Diseases*. 2000;36(6):1089-109. doi: 10.1053/ajkd.2000.19809.
16. **Kitching AR, Anders HJ, Basu N, Brouwer E, Gordon J, Jayne DR, et al.** ANCA-associated vasculitis. *Nat Rev Dis Primers*. 2020;6(1):71. doi: https://doi.org/10.1038/s41572-020-0204-y
17. **Mahr A, Batteux F, Tubiana S, Goulvestre C, Wolff M, Papo T, et al.** Brief Report: Prevalence of Antineutrophil Cytoplasmic Antibodies in Infective Endocarditis: ANCAs in Infective Endocarditis. Arthritis & Rheumatology. 2014;66(6):1672-7. doi: 10.1002/art.38389.
18. **Sugimoto T, Morita Y, Yokomaku Y, Isshiki K, Kanasaki K, Eguchi Y, et al.** Systemic Cholesterol Embolization Syndrome Associated with Myeloperoxidase-anti-neutrophil Cytoplasmic Antibody. *Intern Med*. 2006;45(8):557-61. doi: 10.2169/internalmedicine.45.1553.
19. **Maeshima E.** A case of cholesterol embolism with ANCA treated with corticosteroid and cyclophosphamide. *Annals of the Rheumatic Diseases*. 2001;60(7):726-7. doi: 10.1136/ard.60.7.726

pregunta Dione

Case description

We present the case of a 66-year-old man with a history of smoking, HTN, prediabetes, obesity, knee osteoarthritis, dyslipidemia, nonobstructive nephrolithiasis, and stage 3aAx chronic kidney disease (CKD), with a baseline creatinine of 1.5 mg/dL and an estimated glomerular filtration rate (eGFR) using the CKD-EPI formula of 48 mL/min/1.73 m^2. He also had an infrarenal abdominal aortic aneurysm with progressive growth to more than 5 cm in diameter. Therefore, in January 2023, he underwent aneurysm correction with a stent graft, during which complex aortic atheromatosis was found. He was treated comprehensively with aspirin, clopidogrel, atorvastatin, losartan, empagliflozin and acetaminophen.

One month later, he was hospitalized at Hospital Pablo Tobón Uribe due to accelerated deterioration of his kidney function found on ambulatory visits over the previous four weeks: an initial creatinine of 1.5 mg/dL, progressively

Dionne Line 18/2/25 16:20

Comentario [1]: No estoy familiarizada con la clasificación de la enfermedad renal, particularmente con la abreviación "Ax", y no pude encontrar una explicación al respecto. Favor verificar que lo he empleado bien aquí. Mil gracias!