



<https://doi.org/10.15446/cr.v7n2.88306>

ROSAI-DORFMAN DISEASE: A RARE PRESENTATION OF EXTRANODAL INVOLVEMENT OF ISOLATED BONE. CASE REPORT

Keywords: Histiocytosis, Sinus; Extranodal Extension; Methotrexate; Rosai-Dorfman Disease.

Palabras clave: Histiocitosis Sinusal; Extensión Extranodal; Metotrexato; Enfermedad de Rosai-Dorfman.

Camilo Andrés García-Prada
Tomás Rodríguez-Yanez
Universidad de Cartagena
- Faculty of Medicine -
Cartagena de Indias - Colombia.

Carlos Alberto Ferrer-Santos
Universidad de los Andes
- Faculty of Medicine -
Bogotá D.C. - Colombia.

Corresponding author
Camilo Andrés García-Prada.
Universidad de Cartagena de Indias.
Cartagena de Indias, Colombia.
Correo electrónico: cgarciap4@unicartagena.edu.co

RESUMEN

Introducción. La enfermedad de Rosai-Dorfman, también conocida como histiocitosis sinusal, es un trastorno poco frecuente caracterizado por la proliferación de histiocitos.

Presentación del caso. Hombre de 33 años quien consultó al servicio de urgencias de una institución de tercer nivel de Cartagena de Indias, Colombia, por una deformidad de progresión lenta que apareció 6 meses atrás en el costado frontal derecho de la cara y generaba dolor. Al examen físico no hubo hallazgos mayores y los estudios paraclínicos fueron normales o negativos. Se obtuvieron imágenes que evidenciaron extenso compromiso inflamatorio/infeccioso del hueso frontal, por lo que se sospechó de osteomielitis y se realizó biopsia de la lesión que permitió establecer diagnóstico de enfermedad de Rosai-Dorfman variante extranodal con compromiso óseo aislado. El paciente recibió tratamiento con corticoide sistémico sin obtener respuesta, por lo que se adicionó metotrexato, con lo cual se logró mejoría a los 2 meses.

Conclusiones. Las manifestaciones de la enfermedad de Rosai-Dorfman en población adulta son poco conocidas, además no hay mucha información sobre su tratamiento, por lo que el presente caso contribuye a ampliar la literatura sobre esta enfermedad que puede presentarse con sintomatología completamente inusual.

ABSTRACT

Introduction: Rosai-Dorfman disease (RDD), also known as sinus histiocytosis, is a rare disorder characterized by histiocyte proliferation.

Case presentation: A 33-year-old man consulted the emergency department of a tertiary care institution in Cartagena de Indias, Colombia, due to a 6-month history of progressive deformity in the frontal right side of the face, associated with pain of slow progression, without any other symptoms or dermatological involvement. There were no other major findings on physical examination and laboratory tests performed were negative. Imaging scans obtained showed extensive inflammatory involvement of the frontal bone, which led to suspect osteomyelitis as the first diagnostic possibility. A biopsy of the lesion was performed with negative cultures for bacteria, which allowed establishing a diagnosis of extranodal Rosai-Dorfman disease with isolated bone involvement. Treatment with systemic corticosteroids was indicated with poor response, so methotrexate was added, achieving an evident improvement after 2 months.

Conclusions: Little is known about the manifestations of Rosai-Dorfman disease and its treatment in the adult population. The present case report contributes to expanding the literature on this topic, which can present with rare symptoms that may pose challenges for its diagnosis.

INTRODUCTION

Sinus histiocytosis with massive lymphadenopathy, also known as Rosai-Dorfman disease, was first described by Rosai and Dorfman in 1969. It is a rare histiocytic proliferative disorder of unknown etiology (1), and different cell populations and cytokines are involved in its pathogenesis. The participation of inflammatory cytokines such as macrophage colony stimulating factor, IL-1 β , IL-6, and TNF- α is common (2).

This disease predominantly affects children and young adults in the first 2 decades of life, particularly males. Patients who present with extranodal disease may require systemic therapy, for which there is currently no standardized regimen to date. Systemic therapies include corticosteroids, mTOR inhibitors, radiation therapy, chemotherapy, and immunomodulatory therapy.

CASE DESCRIPTION

A 33-year-old mestizo man from Cartagena - Colombia, who works as a street vendor, of low economic status, without a relevant medical history, consulted due to the presence of a progressive deformity in the right frontal side of the face and pain of 6 months of evolution with slow progression and no other associated symptoms.

On physical examination, he presented with growth of the right frontal region, without the presence of dermatological lesions, lymphadenopathy or visceromegaly. Complementary laboratory tests (complete blood count, blood chemistry, sedimentation rate, C-reactive protein, proteinogram, immunoglobulins, complement, ANA, VDRL, hepatitis and HIV, beta-2-microglobulin and chest radiography) were performed, which were normal or negative. Initial imaging studies showed extensive inflammatory/infectious bone involvement, which led to suspect osteomyelitis as the first diagnostic possibility (Figure 1).

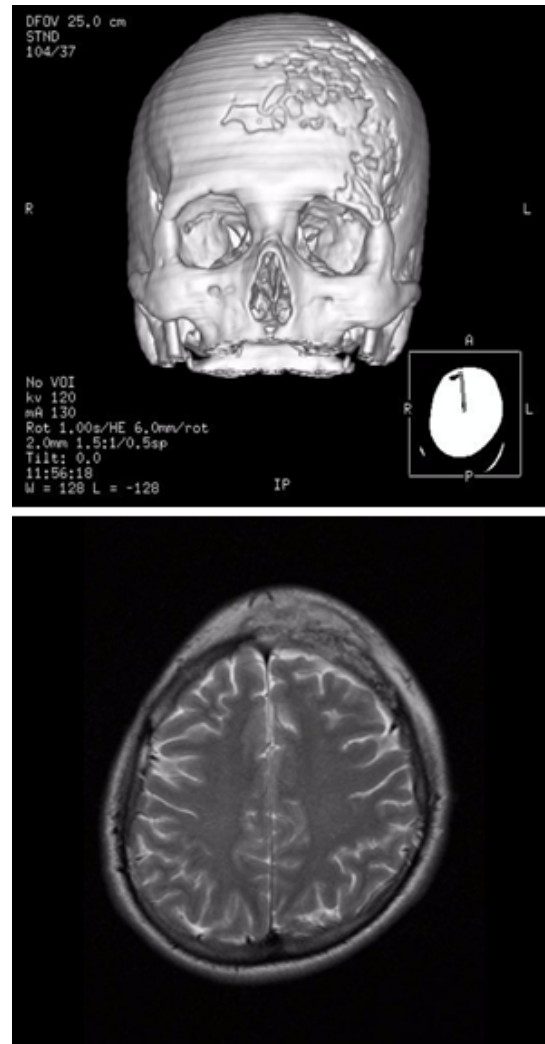

Figure 1. Initial imaging studies of the lesion showing extensive inflammatory bone involvement, with osteomyelitis as the first diagnostic possibility.

Source: Document obtained during the study.

The histopathological study revealed histiocyte sheets at the frontal bone level with clear cytoplasm and rounded nuclei, without significant atypia, lymphocyte and neutrophil emperipolesis, positivity for CD68 and S100, and negativity for CD1a in immunohistochemistry (Figure 2). The microbiological study was negative for fungi, *M. tuberculosis*, atypical mycobacteria and *Leishmania* sp. These findings led to the diagnosis of extranodal Rosai-Dorfman disease with isolated

bone involvement; an extension study was carried out, but no systemic affectation was detected.

Given the possibility of having a self-limited course (50% of cases), medical follow-up was provided for a period of 2 months without achieving improvement. As a consequence, treatment with prednisolone at 1 mg/kg/day was started for 2 months, without obtaining a positive response,

so methotrexate 15 mg/week was initiated with evident improvement, from a clinical perspective, after 2 months due to the improvement of the deformity in the face and imaging scans showing partial resolution of the initial tomographic findings. Throughout the clinical follow-up, no adverse reactions to the use of steroids in conjunction with methotrexate were observed.

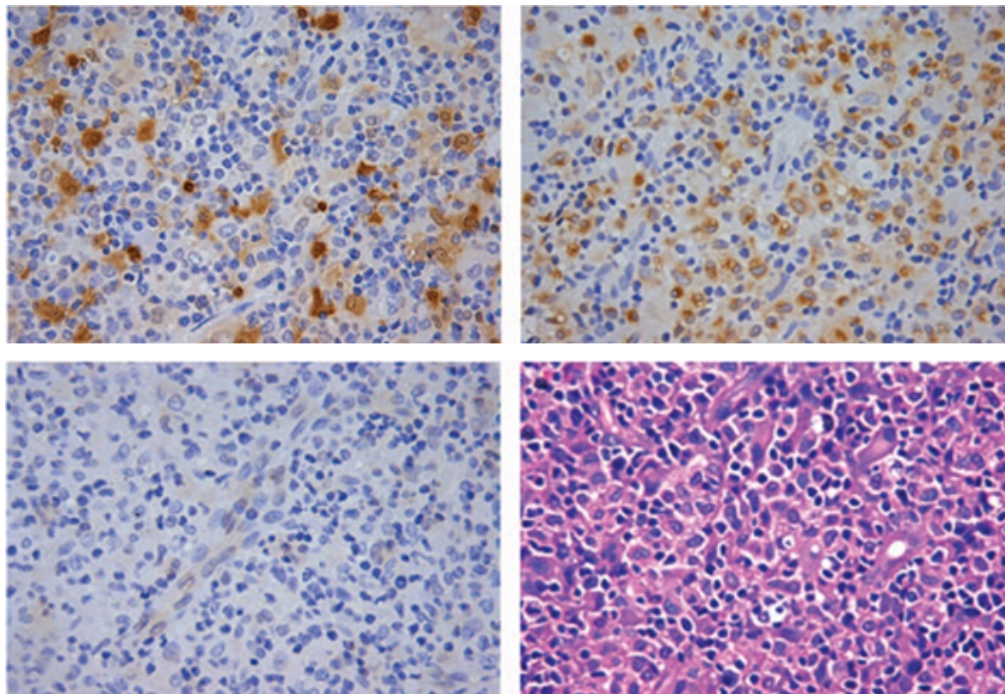


Figure 2. The histopathological study showed histiocyte sheets with clear cytoplasm and rounded nuclei, without significant atypia and lymphocyte and neutrophil emperipolesis. Positivity for CD68 and S100 and negativity for CD1a were found in immunohistochemistry stains.

Source: Document obtained during the study.

DISCUSSION

Rosai-Dorfman disease may occur in any age group; however, its occurrence predominates in children and young adults, particularly males. Its classic clinical presentation is characterized by the appearance of massive and indolent cervical lymphadenopathy with fever, hypergammaglobulinemia and increased erythrocyte sedimentation rate (3). The reported patient did not have these

characteristics since local bone involvement predominated at the level of the cranial vault, being initially managed as an infectious process.

RDD is a benign histiocytic proliferative disorder, with a prevalence of 1:200 000 and an estimated 100 new cases per year in the United States. Its form may be nodal or extranodal. In cases of nodal disease, cervical lymphadenopathy is the most frequent, followed by axillary, inguinal and mediastinal location. On the

other hand, extranodal forms usually affect the central nervous system, skin, soft tissues, bone, oral cavity, and salivary glands (2). Extranodal involvement is frequent and occurs in 43% of patients, mainly in the head and neck. Isolated extranodal presentation may also occur, as in the case of our patient (1).

Isolated bone involvement is a rare manifestation of the disease, occurring in less than 10% of the cases (4). The most common symptoms in this scenario are pain and swelling. Data available in the reviewed literature states that the skull, face and long bones are the most affected areas, with lytic lesions predominantly (4). In contrast to the benign course of nodal manifestations, Rosai-Dorfman disease in the bones has a poorer prognostic factor, as it tends to have a chronic course with frequent relapses.

Imaging scans are useful for the identification, staging and monitoring of the clinical course of the disease with bone involvement. However, this disease may simulate other conditions, including neoplasms (lymphoma, Kaposi's sarcoma, metastasis and malignant histiocytosis) and inflammatory conditions (infections: tuberculosis and histiocytosis; non-infectious granulomatous conditions: Castleman disease, granulomatosis and sarcoidosis) (1). In the present case, scans were interpreted as initially associated with a local infectious process, for which the patient received a course of antibiotics that was suspended based on histological findings.

The course of this disease is usually benign, with frequent cases of spontaneous regression; less than 10% of patients suffer progressive disease associated with adverse outcomes, including death. In most cases documented in the literature, patients usually receive surgical or glucocorticoid-based management. Several treatments, such as systemic corticosteroids, surgery, chemotherapy and radiotherapy, or a

combination of these, have been reported, all with variable efficacy (5). Vincristine and imatinib (6) have demonstrated it to be effective in refractory patients. There have also been reports of patients who responded well to low dosages of methotrexate (7).

Timely diagnosis and treatment based on the descriptions found in the literature allowed for the improvement of the patient's condition, who was previously isolated from his family and social group due to the lack of knowledge on his disease.

CONCLUSION

Extranodal Rosai-Dorfman disease is common; however, isolated bone involvement is rare, accounting for less than 10% of cases. This is an extremely rare disease that poses a diagnostic challenge considering that its clinical suspicion is based on its traditional form of presentation, which was not observed in our patient. In this case, histology and immunohistochemical studies were essential to reach the diagnosis.

ETHICAL APPROVAL

Informed consent was obtained from all participants included in the study.

CONFLICTS OF INTEREST

None stated by the authors.

FUNDING

None stated by the authors.

ACKNOWLEDGEMENTS

None stated by the authors.

REFERENCES

1. **Mar WA, Yu JH, Knuttinen MG, Horowitz JM, David O, Wilbur A, et al.** Rosai-Dorfman Disease: Manifestations Outside of the Head and Neck. *AJR Am J Roentgenol.* 2017;208(4):721-32. <https://doi.org/f93zbn>.
2. **Piris MA, Aguirregoicoa E, Montes-Moreno S, Celeiro-Munoz C.** Castleman Disease and Rosai-Dorfman Disease. *Semin Diagn Pathol.* 2018;35(1):44-53. <https://doi.org/gd53>.
3. **Cai Y, Shi Z, Bai Y.** Review of Rosai-Dorfman Disease: New Insights into the Pathogenesis of This Rare Disorder. *Acta Haematol.* 2017;138(1):14-23. <https://doi.org/gbhkdh>.
4. **Mosheimer BA, Oppl B, Zandieh S, Fillitz M, Keil F, Klaushofer K, et al.** Bone Involvement in Rosai-Dorfman Disease (RDD): a Case Report and Systematic Literature Review. *Curr Rheumatol Rep.* 2017;19(5):29. <https://doi.org/gd54>.
5. **Paryani NN, Daugherty LC, O'Connor MI, Jiang L.** Extranodal rosai-dorfman disease of the bone treated with surgery and radiotherapy. *Rare tumors.* 2014;6(4):5531. <https://doi.org/gd55>.
6. **Utikal J, Ugurel S, Kurzen H, Erben P, Reiter A, Hochhaus A, et al.** Imatinib as a treatment option for systemic non-Langerhans cell histiocytosis. *Arch Dermatol.* 2007;143(6):736-40. <https://doi.org/bv4b58>.
7. **Inoue S, Onwuzurike N.** Venorelbine and methotrexate for the treatment of Rosai-Dorfman disease. *Pediatric Blood Cancer.* 2005;45(1):84-5. <https://doi.org/dwz9tk>.