

# An unexpected pathogen causing multiple intra-abdominal abscesses in an immunocompetent patient

Felipe Vera-Polania<sup>1,a\*</sup>, Lina Marcela Muñoz-Solano<sup>2</sup>, Julián Andrés Hoyos-Pulgarín<sup>3</sup>

## Abstract

*Streptococcus constellatus* is a member of the group now called *Streptococcus anginosus*. This microorganism is part of the normal oropharyngeal, gastrointestinal and genitourinary microbiota. However, it may cause serious infections such as pharyngitis, bacteremia and invasive pyogenic infections in immunocompromised patients. We report the first case in Colombia of an adult male with no relevant medical history and with an unusual presentation of infection by *S. constellatus* and whose laboratory results showed an important systemic inflammatory response and radiographic evidence of abdominal involvement with poor response to medical and surgical management. Since there are few reports in international medical journals about intra-abdominal infection by *S. constellatus* and taking into consideration the need of a multidisciplinary intervention, this report may be of interest for both clinical and surgical practitioners.

**Keywords:** *Streptococcus constellatus*; Gram-Positive Bacterial Infections; Gram-Positive Bacteria; Septic Shock; *Streptococcus anginosus*; Abdominal Abscess (MeSH).

## Un patógeno inesperado como causa de múltiples abscesos intrabdominales en un paciente inmunocompetente

### Resumen

*Streptococcus constellatus* es un miembro del grupo ahora llamado *Streptococcus anginosus*. Este microorganismo es parte de la microbiota orofaríngea, gastrointestinal y genitourinaria normal. Sin embargo, puede causar infecciones graves como faringitis, bacteriemia e infecciones piógenas invasivas en pacientes inmunocomprometidos. Presentamos el primer caso en Colombia de un hombre adulto sin antecedentes médicos relevantes y con una presentación inusual de infección por *S. constellatus*, dada por una gran respuesta inflamatoria sistémica y evidencia radiográfica de afectación abdominal con mala respuesta al tratamiento médico y quirúrgico. Dado que hay pocos informes en revistas médicas internacionales sobre la infección intraabdominal por *S. constellatus* y teniendo en cuenta la necesidad de intervenciones multidisciplinarias, este reporte puede ser de interés tanto para los médicos clínicos como para los quirúrgicos.

**Palabras clave:** *Streptococcus constellatus*; Infecciones por bacterias grampositivas; Bacterias gram-positivas; Shock séptico; *Streptococcus anginosus*; Absceso Abdominal (DeCS).

### Introduction

*Streptococcus constellatus* is formally recognized within the *Streptococcus anginosus* group, which includes two other species, *S. intermedius* and *S. anginosus*<sup>1</sup>. This group frequently includes  $\alpha$ -hemolytic Streptococci, although they may display  $\beta$ -hemolysis or appear as non-haemolytic<sup>2</sup>. It is important to mention that throughout history this group of bacteria has had a confusing and changing classification. They were previously included, as members of a group called *Streptococcus milleri*<sup>1,3</sup>. Even though this term is still used in

the world medical journals literature, the *anginosus* group, proposed by Kawamura in 1995, is currently preferred, eliminating much of the confusion in the nomenclature<sup>4</sup>.

The microorganisms of the group *Streptococcus anginosus* are considered habitual microbiota of the oral cavity, throat, gastrointestinal and genitourinary tract; but they have been associated with serious contiguous or distant purulent infections when mucosal damage occurs especially in immunocompromised patients<sup>4</sup>. This type of compromise corresponds to one of the group's most notable features, which confers it importance

1 Internal Medicine Resident, Universidad del Valle – Hospital Universitario del Valle, Cali, Colombia. <https://orcid.org/0000-0002-4509-6873>

2 Internist, Universidad del Valle – Hospital Universitario del Valle, Cali, Colombia. <https://orcid.org/0000-0002-1215-3069>

3 Infectious diseases specialist, Universidad Pontificia Bolivariana, Medellín, Antioquia, Colombia. <https://orcid.org/0000-0002-2629-5316>

a Grupo y Semillero de Investigación Salud Pública e Infección, Facultad de Ciencias de la Salud, Universidad Tecnológica de Pereira, Pereira, Risaralda, Colombia.

\* Autor para correspondencia.  
Correo electrónico: fvera@utp.edu.co

Recibido: 16/11/2020; Aceptado: 12/12/2020

Cómo citar este artículo: F. Vera-Polania, et al. An unexpected pathogen causing multiple intra-abdominal abscesses in an immunocompetent patient. Infectio 2021; 25(3): 200-205

from the clinical point of view<sup>5</sup>. In this article, we describe the case of an immunocompetent patient with an unusual *S. constellatus* infection with multiorgan involvement.

## Case report

A 46-year-old male, construction worker, presented to the emergency department reporting that he had a moderate intensity epigastric pain during 10 days. The patient also reported fever, fatigue, hyporexia, and diaphoresis predominantly at night. Three days before his admission, he presented melena feces. He had no other medical conditions and no prior surgeries. Tachycardia (HR=122 bpm) and hypotension (AP=87/55 mmHg) were evident on physical examination, in addition to dry, pale mucosa, poor dental hygiene and pain on abdominal palpation.

Laboratory findings at admission showed leukocytosis (45,000/mcL), neutrophils 85%, hemoglobin 7 gr/dl, bandemia (6%), and negative ELISA HIV test. An upper gastrointestinal tract endoscopy revealed a Murakami IV gastric ulcer. His initial treatment was sclerotherapy and transfusion of a globular concentrate.

Initial blood cultures were collected; and empirical treatment was started with ceftriaxone 2gr daily. On the fifth day, the initial blood cultures were reported as negative for this reason he completed 7 days of treatment with antibiotics; at the same time liver tests were documented with altered results.

Thick drop, leptospira IgM, hepatitis A IgM, hepatitis C antibodies, hepatitis B surface antigen, and CMV IgM tests were taken, and they were reported as negative.

After 10 days of hospitalization the patient persisted febrile, and developed a lower extremity edema and ascites. An abdominal ultrasound, showed hypoechoic nodular images in liver segments IV and VIII. An abdominal CT scan, reported poorly defined focal liver lesions, portal vein thrombosis and intra-abdominal free fluid, an evacuation paracentesis of 2.5 liters of a slightly turbid fluid was performed; and it showed 4,712 leukocytes/mL, 70% neutrophils, 590 erythrocytes/mL, 68 mg/dL glucose, 2.8gr/dL proteins, and Gram stain and bacterial cultures incubated for 5 days were negative. The doppler ultrasound of the portal system confirmed portal vein thrombosis and anticoagulation was started with enoxaparin.

On day 12 of hospitalization, the patient continued with signs of inflammatory response, and a new cycle of empirical antibiotic therapy was initiated with meropenem 1 g intravenous solution every 8 hours for 7 days with general improvement. Subsequently, the patient presented fever again and abdominal pain in the right hypochondrium, with new negative blood cultures. The febrile episodes increased in frequency; and the patient persisted with leukocytosis, neutrophilia and procalcitonin higher than 200 ng/ml, Table 1 and Table 2 summarizes the results of the laboratory tests described in the case. The blood cultures were repeated, and they reported gram positive cocci which were typified as *Streptococ-*

**Table 1.** Results of the laboratory tests described in the case.

TEST		RESULTS			REFERENCE RANGE
		Day 7	Day 10	Day 16	
White cell count	45.000 /L	29700 /L	37000 /L	42200/L	4.000 – 11.000/L
Neutrophils	85%		79%	87%	
Hemoglobin	7 g/dl	8,6 g/dl	8,2 g/dl	7,1 g/dl	13,5 – 17,5 g/dl
AST		128			6 – 34 IU/L
ALT		279			20 – 60 IU/L
Total bilirubin		4,5			1,0 mg/dl
Direct bilirubin		2,38			<0,2 mg/dl
Procalcitonin				>200	

**Table 2.** Results of the infectious tests described in the case.

Infectious Test	Results			
	Day 1	Day 7	Day 10	Day 16
HIV Elisa	Negative			
Blood culture	Negative			<i>Streptococcus constellatus</i>
Thick gout		Negative		
IgM Leptospira		Negative		
IgM Hepatitis A		Negative		
Hepatitis C Antibodies		Negative		
Hepatitis B surface antigen		Negative		
Citomegalovirus IgM		Negative		
Ascitic cultures			Negative	
Perihepatic collection culture				<i>Streptococcus constellatus</i>

*cus constellatus ssp. constellatus* susceptible to penicillin (MIC <0.12 ug/mL) (Figure 1). Management was started with crystalline penicillin 30 million units daily by continuous intravenous infusion and intravenous moxifloxacin 400 mg daily.

An abdominal ultrasound was performed again; it showed an echogenic right subphrenic and perihepatic collection of 6x3cm, focal lesions of segment IV and VIII of the liver and a pelvic collection, anterior and superior to the bladder, of 9.1x8, 4x11cm. A CT guided percutaneous drainage was performed (Figure 2), obtaining 800cc of foul-smelling purulent material at subphrenic and pelvic level. A sample was sent for culture obtaining *Streptococcus constellatus ssp constellatus* (Figure 3). Drainage catheters were left which constant production.

It was decided to perform a surgery on the patient, and multiple foci were found in the intestinal loops. After surgical lavage, the patient was transferred to the ICU for monitoring, but he presented multi-organ failure and died. It is considered that the possible infectious origin was at the oral cavity level.

## Discussion

As previously mentioned the members of this group, *S. anginosus*, are normally commensal pathogens found in the oropharyngeal, gastrointestinal and genitourinary microbiota<sup>5,6</sup>, but in the case of manipulations of the digestive or respiratory tract they can cause a great variety of abscesses in the abdominal cavity, lower respiratory tract, urogenital tract, orofacial region and in the skin<sup>3</sup> as reported in different cases<sup>7,8</sup>, in contrast to this case, which had no history of surgical intervention and possible odontogenic foci. Binding of bacteria to extracellular matrix proteins is a common pathogenicity mechanism of streptococci that has been extensively studied and can also be observed in *S. anginosus* group. *Streptococcus anginosus* is typically found in the biofilm of dental plaque and adhesins play an important role in colonization of the oral cavity but it is also crucial for manifestation of clinical infections. A highly significant correlation between the binding to saliva-coated hydroxyapatite and the ability to bind fibronectin were observed. This would explain the relationship between periodontal disease, poor dental hygiene and the development of invasive bacterial infections by members of this group<sup>9</sup>. Other examples of identified *Streptococcus anginosus* group

virulence factors include sialidase produced by *S. intermedius*, intermedilysin - a cholesterol dependent cytolysin, which is probably involved in disease invasiveness as its level is high in abscesses and low in dental plaque, or chondroitin sulfate depolymerase and hyaluronidase. One of the most interesting discoveries regarding *Streptococcus anginosus* group virulence factors is the recent detection of genes encoding superantigens *speC* and *speG* and DNAses encoded by *sdC* and *sdA* that were presumably transferred between species<sup>10</sup>.

In addition, metastatic abscesses in the brain, liver, spleen, bone, as well as endocarditis originating hematogenously have been described<sup>5</sup>. Furthermore, some studies have identified that members of this bacterial group have great etiological importance in the pulmonary exacerbations of patients with cystic fibrosis<sup>11</sup>. Recent analyses suggests that the number of infections caused by *Streptococcus anginosus* group is heavily underestimated. New data estimate the incidence of invasive *Streptococcus anginosus* group infections to be 8.65/100,000 population and 8.8/10,000 among hospitalized patients<sup>10</sup>.

It has been suggested that the different species of this group are associated with specific clinical syndromes. For example, *S. constellatus* is associated with thoracic infections, *S. intermedius* with central nervous system infections and *S. anginosus* with gastrointestinal and urogenital infections. However, a statistically significant correlation has not been demonstrated<sup>12,13</sup>. It is also known that patients with liver cirrhosis, cancer and diabetes mellitus are at greater risk of disseminated infections caused by the *S. anginosus* group<sup>12</sup>.

In this case, diagnosis was made with VITEK 2 automated system (bioMérieux, Marcy l'Etoile), which from an inoculum, from a previously purified culture, performs a series of biochemical tests that deliver highly sensitive and specific results<sup>14,15</sup>.

In regard to treatment of infections by *S. anginosus* group microorganisms, they are known to be susceptible to penicillin, and for this reason, taxonomic classification up to the species level is not routinely carried out<sup>13</sup>. Specifically in relation to *S. constellatus* infection, it is known that these microorganisms show susceptibility to  $\beta$ -lactam antibiotics, doxycycline, erythromycin, vancomycin, and intermediate susceptibility to clindamycin is also reported<sup>16</sup>. Despite its good response to antibiotic therapy, an increase in resistance to penicillin and clindamycin has been described in different studies<sup>17</sup>. In one study subgingival isolates of *S. constellatus* and *S. intermedius* in vitro were all or nearly all susceptible to amoxicillin, clindamycin, and azithromycin, only intermediate in susceptibility to ciprofloxacin, frequently resistant to doxycycline, and nearly all resistant to metronidazole. Subgingival *S. constellatus* and *S. intermedius* exhibited variable antibiotic susceptibility profiles, potentially complicating empiric selection of periodontitis antibiotic therapy in species-positive patients<sup>18</sup>. It is speculated that abscesses in sterile sites of the host organism are probably formed as a result of the high resistance of *S. anginosus* group to phagocytosis and inhibition of chemotaxis<sup>10</sup>. The *S. angino-*

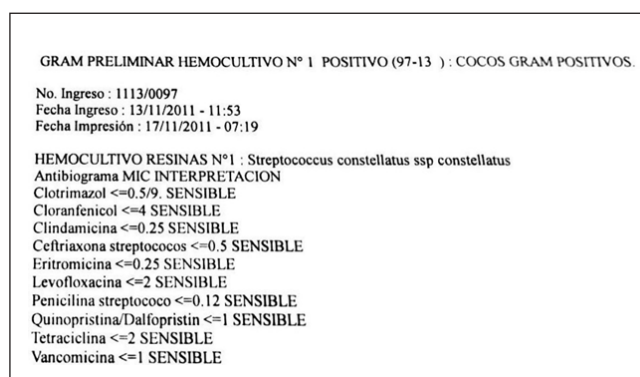
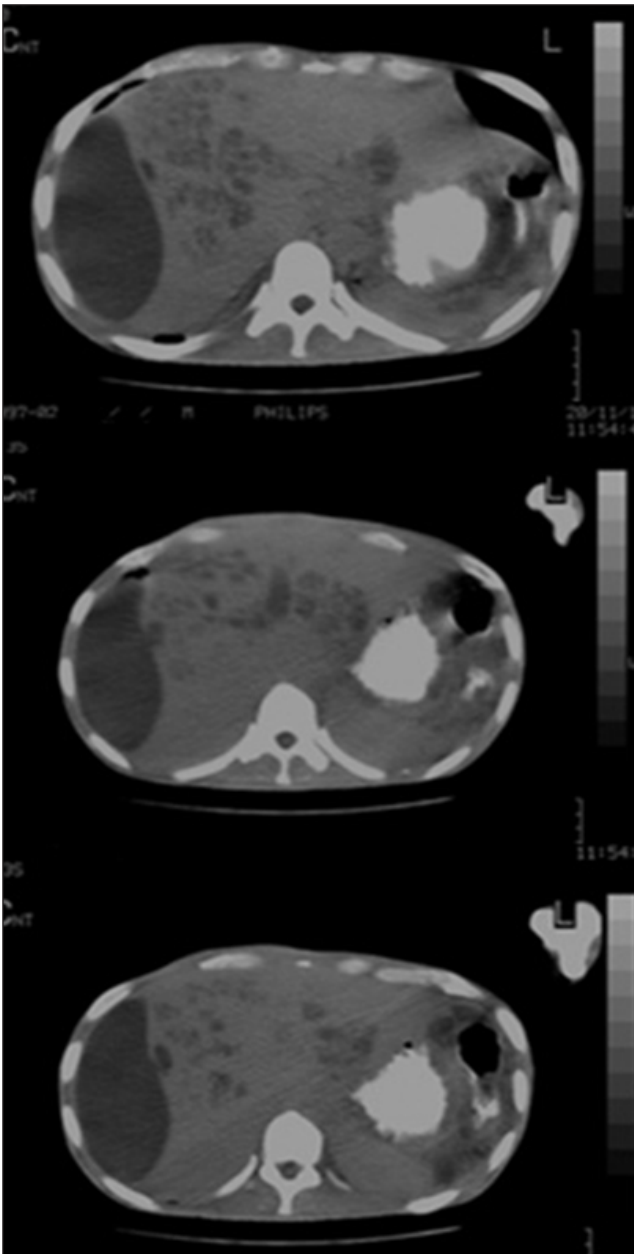


Figure 1. Antibiogram of *Streptococcus constellatus* isolates in blood culture

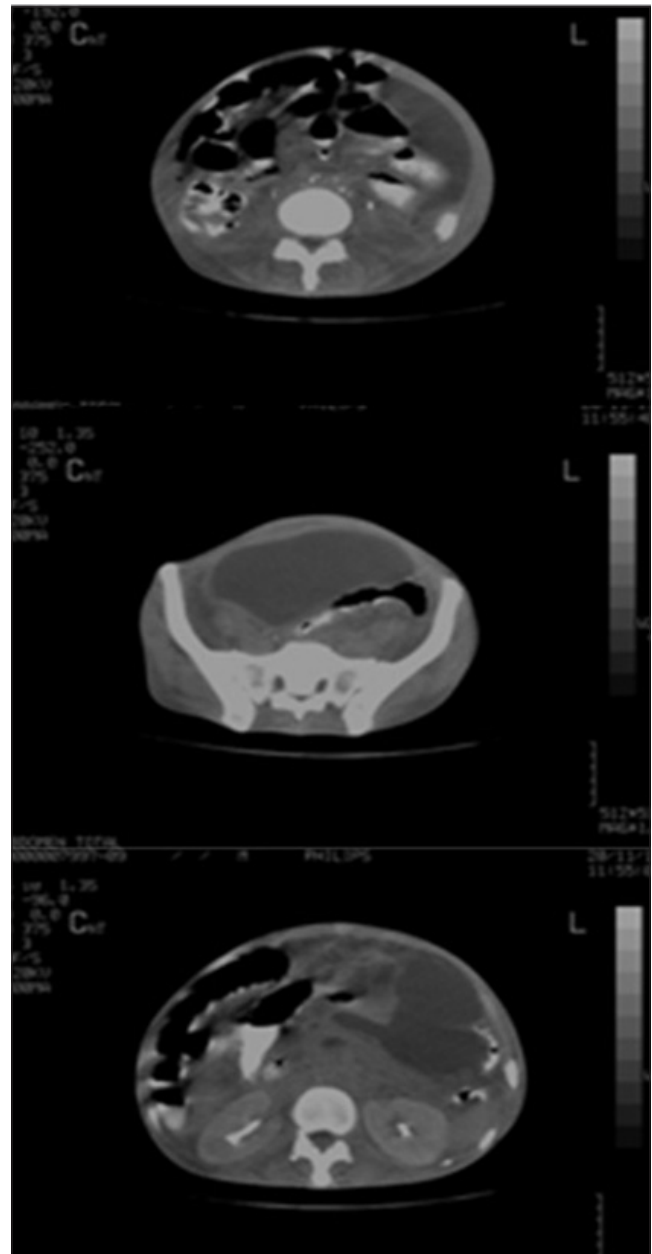


**Figure 2a.** Subphrenic collection. Double contrast abdominal CT.

*sus* group capsule is one of the better characterized virulence factors. Encapsulated strains are more virulent in the murine abscess model as the capsule affects phagocytosis and neutrophil killing. Possible molecular mechanisms involved in that process may also include the production of hydrogen sulfide from L-cysteine by L-cysteine desulfhydrase<sup>10</sup>.

In addition to parenteral antimicrobial therapy, the treatment of an abscess involves the drainage of purulent material. The sole medical therapy should be reserved for patients with multiple and/or small, well-defined lesions or when patients are at high risk of surgical complications<sup>12</sup>.

In this case, the *S. constellatus* strain had a susceptibility spectrum to penicillin (MIC <0.12 ug/mL) which allowed to define management with crystalline penicillin and moxifloxacin 400



**Figure 2b.** Pelvic collection. Double contrast abdominal CT.

mg due to infections diseases recommendation. Given the high rate of susceptibility to penicillin, this drug remains the first line of treatment<sup>19</sup>. In addition, intraabdominal infections are usually polymicrobial, studies have reported that the incidence of polymicrobial bacteremia was as high as 51%<sup>19</sup>, in one study liver abscesses were associated with polymicrobial infections in 50% of the cases<sup>20</sup>, Clarridge et al. reported that *S. intermedius* tends to be isolated as a sole pathogen, whereas *S. anginosus* and *S. constellatus* are associated with polymicrobial infections<sup>5</sup>. The results of one report pooling 4 well-controlled trials<sup>21</sup>, supports the asseveration that moxifloxacin is efficacious for the treatment of intra-abdominal infections caused by a broad range of anaerobic and aerobic bacteria, being coherent with the published SIS and IDSA guidelines, which recommend moxifloxacin for the treatment of mild-to-moderate community-acquired intra-abdominal infections<sup>21</sup>.

Based on the result of abdominal CT, a percutaneous drainage was performed in which the growth of the bacteria was evidenced. This along with the positive blood cultures allows to infer the capacity that this microorganism has to produce metastatic infections which must be properly identified and treated to avoid persistence of the infection.

Although typifying this group at the species level is not essential to start treatment, It is suggested that this taxonomic identification has prognostic importance, because of the loss of life in 30 days and the average length of hospital stay being significantly higher in *S. intermedius* infections than in patients infected with *S. constellatus* and *S. anginosus*<sup>11</sup>, with a general mortality rate of 16% found for all subspecies<sup>11</sup>. In this sense, prospective studies are necessary to verify whether infection by a specific species of the group is a prognostic factor of the severity of the infection and of the clinical outcome.

This patient illustrates an unusual infection with multiple intra-abdominal abscesses, sepsis and septic shock with subsequent multiorgan failure by *Streptococcus constellatus*. It is also observed that despite having a trained team of doctors, the facilities provided by a regional hospital in terms of diagnostic methods and adequate treatment based on surgical drainage and susceptibility spectrum, the result was not what it was expected. This highlights the relevance of early diagnosis.

## Acknowledgments

This clinical case was presented at XXVI Congreso Estudiantil Colombiano de Investigación Médica-CECIM, June 03 - 06, 2015, Cali, Colombia, where it was awarded the third place in the clinical case contest.

## Ethical disclosure

Conflict of interest. None

Sources of funding for our research. Authors

CULTIVOS DRENAJE ABDOMINAL: *Streptococcus constellatus* ssp *constellatus*

No. Ingreso : 1122/0142  
Fecha Ingreso : 22/11/2011 - 11:18  
Fecha Impresión : 25/11/2011 - 15:23

CULTIVOS PARA MICROORGANISMOS DRENAJE ABDOMINAL

*Streptococcus constellatus* ssp *constellatus*  
Antibiograma MIC INTERPRETACION  
Clotrimazol <=0.5/9. SENSIBLE  
Cloranfenicol <=4 SENSIBLE  
Clindamicina <=0.25 SENSIBLE  
Ceftriaxona streptococos <=0.5 SENSIBLE  
Eritromicina <=0.25 SENSIBLE  
Levofloxacin <=2 SENSIBLE  
Penicilina streptococo <=0.12 SENSIBLE  
Quinopristina/Dalfopristin <=1 SENSIBLE  
Tetraciclina <=2 SENSIBLE  
Vancomicina <=1 SENSIBLE

**Figure 3.** Antibiogram of *Streptococcus constellatus* isolates in sample of purulent material at subphrenic and pelvic level.

**Protection of human and animal subjects.** Written informed consent was obtained from the patient for publication of this case report and accompanying images.

**Confidentiality of data.** No data that identifies patient are revealed

## References

- Jensen A1, Hoshino T, Kilian M. Taxonomy of the Anginosus group of the genus *Streptococcus* and description of *Streptococcus anginosus* subsp. *whileyi* subsp. nov. and *Streptococcus constellatus* subsp. *viborgensis* subsp. nov. *Int J Syst Evol Microbiol.* 63 (Pt 7), 2506-2519, 2013.
- Ng KW, Mukhopadhyay A. *Streptococcus constellatus* bacteremia causing septic shock following tooth extraction: a case report. *Cases J.* 2:6493, 1-4, 2009.
- Díaz Peromingo JA, Sánchez Leira J, García Suárez F, Padín Paz E, Saborido Froján J. *Streptococcus constellatus* as a causative agent of empyema: Report of one case. *Rev. méd. Chile.* 134(8), 1030-1032, 2006.
- Jacobs JA, Schouls LM, Whiley RA. DNA-DNA reassociation studies of *Streptococcus constellatus* with unusual 16S rRNA sequences. *Int J Syst Evol Microbiol.* 50(1), 247-249, 2000.
- Claridge JE 3rd, Attorri S, Musher DM, Hebert J, Dunbar S. *Streptococcus intermedius*, *Streptococcus constellatus*, and *Streptococcus anginosus* ("Streptococcus milleri Group") Are of Different Clinical Importance and Are Not Equally Associated with Abscess. *Clin Infect Dis.* 32(10), 1511-1515, 2001.
- Sibley CD, Parkins MD, Rabin HR, Duan K, Norgaard JC, Surette MG. A polymicrobial perspective of pulmonary infections exposes an enigmatic pathogen in cystic fibrosis patients. *Proc Natl Acad Sci U S A.* 105(39), 15070-15075, 2008.
- Priya D, Gursimram K, Jagdish C, Ashok K. *Streptococcus constellatus* causing multiple liver abscesses: an elusive pathogen. *Trop Doct.* 2018 Apr;48(2):154-156.
- Bonnet EP, Arista S, Archambaud M, et al. *Streptococcus milleri* group infection associated with digestive fistula in patients with vascular graft: report of seven cases and review. *Infection.* 2007;35(3):182-185.
- Asam, D. and Spellerberg, B. (2014), Molecular pathogenicity of *Streptococcus anginosus*. *Mol oral Microbiol*, 29: 145-155.
- Sitkiewicz I. How to become a killer, or is it all accidental? Virulence strategies in oral streptococci. *Mol Oral Microbiol.* 2018 Feb;33(1):1-12.
- Porta G1, Rodríguez-Carballeira M, Gómez L, et al. Thoracic infection caused by *Streptococcus milleri*. *Eur Respir J.* 12, 357-362, 1998.
- Giuliano S1, Rubini G, Conte A, et al. *Streptococcus anginosus* group disseminated infection: case report and literature review. *Infez Med.* 20(3), 145-154, 2012.
- Junckerstorff RK, Robinson JO, Murray RJ. Invasive *Streptococcus anginosus* group infection—does the species predict the outcome? *Int J Infect Dis.* 18, Pages 38-40, 2014.
- Oderiz S, Palau MJ, Del Palacio P, et al. Evaluación de los sistemas comerciales automatizados VITEK 2 y API 20NE para la identificación de organismos del complejo *Burkholderia cepacia* aislados de muestras clínicas. *Rev argent microbiol.* 43(3), 168-175, 2011.
- Gómez-Garcés JL, Aracil B, Gil Y. Comparison between agar dilution and three other methods for determining the susceptibility of 228 clinical isolates of non-fermenting gram-negative rods. *Enferm Infecc Microbiol Clin.* 27(6), 331-337, 2009.
- Nalmas S, Bishburg E, Chan T. *Streptococcus constellatus* and *Prevotella bivia* Penile Abscess. *Scientific World Journal.* 7, 1631-1633, 2007.
- Tracy M, Wanahita A, Shuhatovich Y, Goldsmith EA, Claridge JE, Musher DM. Antibiotic Susceptibilities of Genetically Characterized *Streptococcus milleri* Group Strains. *Antimicrob Agents Chemother.* 45(5), 1511-1514, 2001.
- Rams TE, Feik D, Mortensen JE, Degener JE, van Winkelhoff AJ. Antibiotic susceptibility of periodontal *Streptococcus constellatus* and *Streptococcus intermedius* clinical isolates. *J Periodontol.* 2014 Dec;85(12):1792-8.
- Suzuki H, Hase R, Otsuka Y, Hosokawa N. Bloodstream infections caused by *Streptococcus anginosus* group bacteria: A retrospective analysis of 78 cases at a Japanese tertiary hospital. *J Infect Chemother* (2016), 1 – 5.
- Fazili T, Riddell S, Kiska D, Endy T, Giurgea L, Sharnogoe C, Javadi W. *Streptococcus Anginosus* Group Bacterial Infections. *Am J Med Sci.* 2017 Sep;354(3):257-261.
- Goldstein, E. J. C., Solomkin, J. S., Citron, D. M., & Alder, J. D. (2011). Clinical Efficacy and Correlation of Clinical Outcomes With In Vitro Susceptibility for Anaerobic Bacteria in Patients With Complicated Intra-abdominal Infections Treated With Moxifloxacin. *Clinical Infectious Diseases*, 53(11), 1074-1080.