

DOI: <https://doi.org/10.5554/22562087.e1015>

Intraoperative adenosine for pheochromocytoma with myocardial infarction and SARS-CoV-2. Case report

Adenosina intraoperatoria para feocromocitoma con infarto miocárdico y SARS-CoV-2. Reporte de caso

María Alonso Alonso^a , Víctor Morales Ariza^a , Yuri Loaiza Aldeán^a , Marcos de Miguel Negro^a , Olga Martínez Silva^a , Anna Casteràs Román^b

^a Anesthesiology and Resuscitation Service, Hospital Universitari Vall d'Hebron. Barcelona, Spain.

^b Endocrinology and Nutrition Service, Hospital Universitari Vall d'Hebron. Barcelona, Spain.

Correspondence: Anesthesiology and Resuscitation Service, Hospital Universitari Vall d'Hebron. Passeig de la Vall d'Hebron, 119-129, 08035. Barcelona, Spain.

Email: vmorales@vhebron.net

How to cite this article: Alonso Alonso M, Morales Ariza V, Loaiza Aldeán Y, de Miguel Negro M, Martínez Silva O, Casteràs Román A. Intraoperative adenosine for pheochromocytoma with myocardial infarction and SARS-CoV-2. Case report. Colombian Journal of Anesthesiology. 2022;50:e1015.

Abstract

Pheochromocytomas are neuroendocrine tumors capable of synthesizing, storing and releasing catecholaminergic hormones that may lead to life-threatening hemodynamic instability. The COVID-19 pandemic has increased the risks and perioperative complexity of the patients undergoing pheochromocytoma-associated adrenalectomy. This article discusses the use of adenosine for the management of hypertensive crisis during this intervention, as well as the need to individualize the suitable timing for surgery after recent COVID-19 infection.

This article discusses the case of a patient with a finding of right adrenal incidentaloma; further studies determined a metanephrines secreting pheochromocytoma. Following hospital admission for preoperative optimization, the eve of the procedure the patient developed an acute myocardial infarction and subsequently SARS-CoV-2 symptomatic infection. Intraoperatively, hypertensive peaks were managed with continuous adenosine perfusion. The patient was discharged after 48 hours.

Preoperative optimization positively influences the intraoperative management of patients with pheochromocytoma. The intraoperative use of adenosine allows for adequate and safe control of hypertensive crises. Each situation must be individualized in patients pending surgery, with a recent COVID-19 infection.

Key words: Pheochromocytoma; COVID-19; Catecholamine; Hemodynamic monitoring; Adenosine triphosphate; Adrenergic antagonists; Anesthesiology.

Resumen

Los feocromocitomas son tumores neuroendocrinos capaces de sintetizar, almacenar y liberar hormonas catecolaminérgicas que pueden provocar inestabilidad hemodinámica con compromiso vital. La pandemia por COVID-19 ha aumentado los riesgos y la complejidad perioperatoria de los pacientes sometidos a adrenalectomía por feocromocitoma. Describimos el uso de adenosina para manejar las crisis hipertensivas durante esta intervención, así como establecer la necesidad de individualizar el momento quirúrgico idóneo tras infección reciente por COVID-19.

Presentamos el caso de un paciente con hallazgo de incidentaloma suprarrenal derecho cuya ampliación de estudio se orientó como feocromocitoma secretor de metanefrinas. Tras ingreso hospitalario para optimización preoperatoria, el día previo al procedimiento presentó un infarto agudo de miocardio y posteriormente una infección sintomática por SARS-CoV-2. Intraoperatoriamente se manejaron los picos hipertensivos con perfusión continua de adenosina. Tras 48 horas recibió el alta hospitalaria.

La optimización preoperatoria influye positivamente en el manejo intraoperatorio de los pacientes con feocromocitoma. El uso intraoperatorio de adenosina permite un adecuado y seguro control de las crisis hipertensivas. En pacientes pendientes de cirugía con infección reciente por COVID-19 se requiere individualizar cada situación.

Palabras clave: Feocromocitoma; COVID-19; Catecolamina; Monitorización hemodinámica; Adenosina trifosfato; Antagonistas adrenérgicos; Anestesiología.

Lea la versión en español de este artículo en www.revcolanest.com.co

Copyright © 2022 Sociedad Colombiana de Anestesiología y Reanimación (S.C.A.R.E.).

This is an open access article under the CC BY-NC-ND license (<http://creativecommons.org/licenses/by-nc-nd/4.0/>).

INTRODUCTION

Pheochromocytomas are rare neuroendocrine tumors of the adrenal medulla; their prevalence in hypertensive individuals ranges from 0.1 % to 0.6 %. They may synthesize, store and secrete adrenaline, noradrenaline and/or dopamine. Their massive release, particularly during the induction of anesthesia and surgical resection may result in life-threatening cardiovascular complications. (1,2)

The preoperative use of α -adrenergic and β -adrenergic antagonists is associated with a drastic reduction in perioperative mortality. Preoperative antihypertensive therapy (PAHT) lasts between 7 and 14 days, and is often administered in hospital. (3) Notwithstanding the optimization, the occurrence of intraoperative hypertensive episodes may be unavoidable. (4) Multiple drugs have been used to control intraoperative hypertensive crises during pheochromocytoma resection, including nitroprussiate, nitroglycerine, magnesium or clevidipine. (5) In this regard, adenosine is a potent, fast, and short-acting vasodilator which can prove to be very useful for blood pressure control during this surgical intervention.

Moreover, on March 11, 2020, the WHO declared the SARS-CoV-2 COVID-19 pandemic. (6) Health institutions transformed their facilities into COVID-19

rooms and critical care units. However, SARS-CoV-2 may spread throughout the hospital facilities, leading to outbreaks with high mortality rates.

This report discusses a case to highlight individualized care at the time of surgery and the intraoperative management of a hypertensive crisis with adenosine in a patient undergoing laparoscopic pheochromocytoma-associated adrenalectomy; during the preoperative hospitalized period, the patient presented with an acute myocardial infarction (AMI) and SARS-CoV-2 respiratory infection.

CASE DESCRIPTION

This is a case of a 79-year old male, with no known allergies, a history of hypertension, dyslipidemia, diabetes mellitus type 2, stage IIIA chronic kidney disease, three-vessel ischemic heart disease which was surgically revascularized with a quadruple bypass in 2013, with preserved left ventricular ejection fraction and moderate restrictive ventilatory dysfunction.

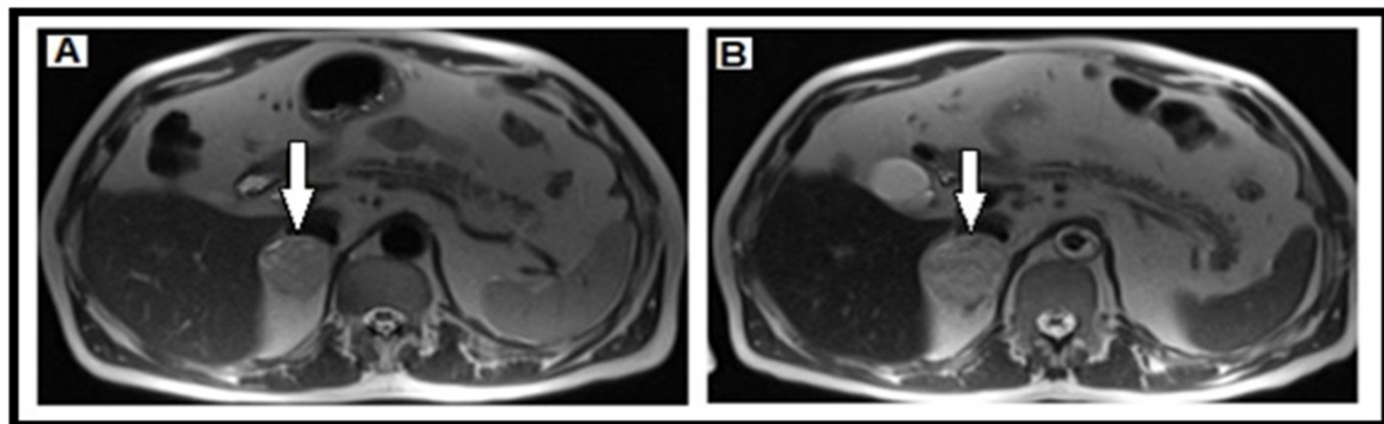
The control abdominal computerized tomography for a urinary bladder neoplasia identified a right adrenal nodular incidentaloma of 37 × 33 mm. The study was expanded with an MRI (Figure 1A) and a scintigraphy showing MIBG radioisotope enhancement in the

right adrenal mass and elevated plasma metanephrines (metanephrine 1,063 pg/mL and normetanephrine 1,274 pg/mL) and urine (normetanephrine 1,466 pg/mL and metanephrine 1,992 pg/mL). The patient presented with a blood pressure in the upper high normal level, with no associated hypertensive crises or a clinical presentation suggestive of catecholaminergic discharge. The patient was scheduled for right laparoscopic adrenalectomy.

The patient was admitted 10 days prior to surgery to undergo α -blocker treatment with doxazosin 4 mg every 6 hours, followed by bisoprolol 2.5 mg every 24 hours. During hospitalization the patient exhibited blood pressure levels of around 130-140/80-90 mmHg and orthostatic hypotension, with a pressure drop down to 100-110/70-75 mmHg.

On the eve of surgery, the patient presented with a clinic compatible with AMI, with non-ST elevation in V1, V2 and V3, and elevated troponins. The patient was admitted to the Coronary Care Unit (CCU) with a diagnosis of non—ST-segment elevation acute myocardial infarction Killip II. Dual anti-aggregation therapy was initiated and nitroglycerin perfusion, which initially managed to control the blood pressure and electrical changes retrograding. The cardiac catheterization revealed that the previous bypass was patent. While in the CCU the patient was

FIGURE 1. MRI of the right adrenal gland (arrow). a) Before the acute myocardial infarction, and b) after acute myocardial infarction, showing enlarged size, and necrotic and hemorrhagic foci inside.



SOURCE: Authors.

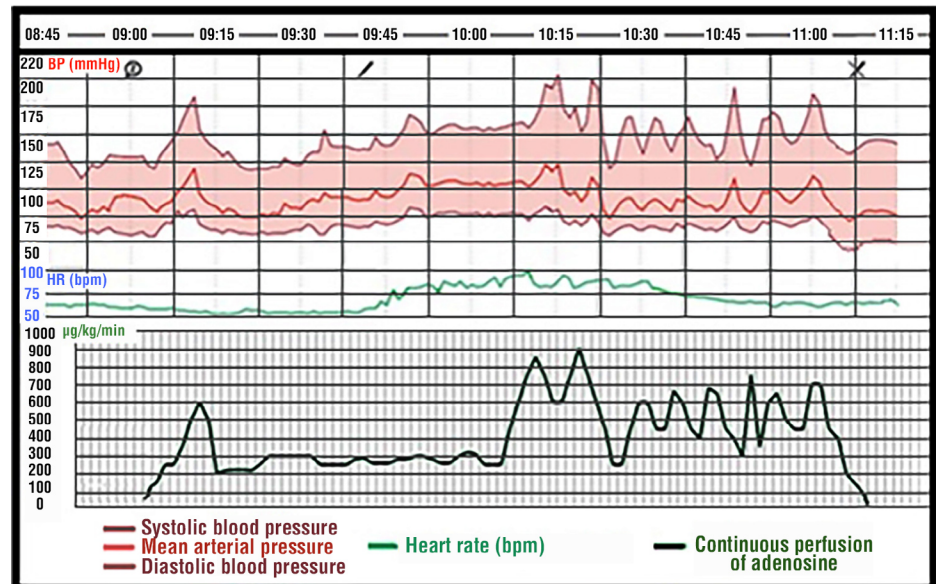
hemodynamically labile, with alternating episodes of hypertensive crises of up to 280 mmHg of systolic blood pressure (SBP), with hypotensive events of up to 60 mmHg SBP, including one atrial fibrillation episode. With the suspicious pheochromocytoma pending intervention as the underlying cause, an MRI showed an enlarged adrenal gland (50 × 40 mm) with signs of new onset internal necrosis (Figure 1B).

Once the cardiac event was under control, the patient was transferred to a hospitalization floor and the surgery was rescheduled. A PCR test for SARS-CoV-2 was administered 48 hours previous to the intervention, and the result was positive. Subsequently, the patient developed moderate hypoxic respiratory failure requiring supplemental oxygen with a Venturi-type mask (FiO₂ 45 %). The radiological studies showed bilateral diffuse infiltrates with a redistribution pattern, for which dexamethasone 6 mg a day and furosemide 40 mg therapy every 12 hours was initiated. The adrenalectomy was adjourned once again.

After a satisfactory respiratory evolution, oxygen therapy was progressively de-escalated until its complete removal. Four weeks after the onset of the infection, a new PCR was done with a positive result and a blood serology showing IgG antibodies, suggesting that the acute infection was over. Once again, the patient underwent the presurgical preparation for pheochromocytoma and after optimization was rescheduled for surgery.

Prior to the intervention, the patient received 2 mg of midazolam and was transferred to the OR, where TIVA-TCI (Total Intravenous Anesthesia – Target Controlled Infusion) was initiated with propofol Ce (Concentration effect) 1.5 µg/mL and remifentanyl Ce 1 ng/mL, maintaining the bispectral index (BIS) between 70–80 and the left radial artery was catheterized for invasive hemodynamic, heart rate and systolic volume variation monitoring using the Vigileo® system. The induction of anesthesia was with TIVA-TCI: propofol Ce 2–4 µg/mL and remifentanyl Ce 2–4 ng/mL

FIGURE 2. Intraoperative BP (mmHg), HR (bpm) monitoring and continuous adenosine infusion progress (µg/kg/min). Induction of anesthesia at 8:55 h, start of surgery 9:42 h and completion at 11:07 h.



SOURCE: Authors.

for BIS 40–60, rocuronium 0.6 mg/kg and lidocaine 1 mg/kg, continuing the with the orotracheal intubation until a TOF (Train of Four) of 0 was achieved, using a video laryngoscope to minimize the adrenergic input. Once the airway was secured and ventilatory assistance was in place, a central venous catheter in the right jugular artery was placed under US-guidance and a 16-G peripheral venous catheter in the left basilic vein. Before the start of surgery, a bilateral TAP (Transversus Abdominis Plane) block was administered with 20 ml of ropivacaine 0.3 % on each side.

The initial tumor manipulation caused an episode of tachycardia with a 30 % increase versus the patient's baseline rhythm and hypertensive peaks of up to 210 mmHg of SBP (Figure 2). A continuous perfusion of adenosine 1% at 89 µg/kg/min was initiated and progressively titrated up to 889 µg/kg/min to control those hypertensive peaks and urapidil and esmolol were administered up to a total of 50 mg and 100 mg, respectively, fractionated throughout the intervention, which allowed for proper blood pressure and

heart rate control. Once the adrenalectomy was completed, the continuous adenosine perfusion was tapered down. There was no evidence of arrhythmias or acute repolarization alterations; the sinus rhythm was maintained and a PR interval within the normal parameters, with a maximum heart rate of 92 bpm. The patient was extubated uneventfully, transferred to the post-surgical recovery room and 48 hours later was discharged. The follow-up was for 90 days, and the patient had no complications.

DISCUSSION

Hemodynamic stability during the pheochromocytoma surgery with absent or inadequate preoperative antihypertensive treatment (PAHT) is associated with a high mortality. Hence, PAHT is recommended in patients with significant or paroxysmal hypertension and normotensives. In this case, the PAHT could not be administered in the conventional manner and had to be discontinued in several occasions. Firstly, on the eve of surgery the patient experienced

an AMI triggered by a catecholaminergic discharge requiring CCU admission and treatment. Secondly, following the recovery of the cardiology episode, the patient developed a SARS-CoV-2-associated acute respiratory syndrome requiring several days of oxygen therapy. After recovering from COVID-19, the patient was re-scheduled. All of these complications increase the perioperative risks of a high risk pathology such as pheochromocytoma.

It is still unknown whether the risk of developing COVID-19 increases in patients with pheochromocytoma (7). However, the pathophysiological changes secondary to the continuous body exposure to large concentrations of catecholamines, results in the development of hypertension, cardiomyopathies, tachyarrhythmias, hypercoagulability, immune deregulation or diabetogenic status which are in themselves risk factors for the development of severe forms of SARS-CoV-2. Additionally, catecholamines have shown to play a key role in the pathophysiology of COVID-19 (8). This fact would justify that in patients where both conditions co-exist, their approach should be early, individualizing (9) the best timing for surgery based on the clinical condition, to prevent the development of potential life-threatening complications to the patient. In view of the comorbidities and the constant threat of the pheochromocytoma-associated catecholaminergic activity, it was considered reasonable to do the surgery five weeks after the COVID-19 contagion, with positive IgG and clinically asymptomatic.

Intraoperative anesthesia management of the pheochromocytoma requires preventing potential triggers of adrenergic crises. It is essential to achieve a deep anesthetic plane and an excellent hemodynamic control during orotracheal intubation. Moreover, abdominal wall blocks allow for proper analgesic control during abdominal bloating from the laparoscopic approach.

Hemodynamic changes during pheochromocytoma surgery develop very rapidly; hence the need to control them

with as fast acting and reversal agents as possible. During the tumor manipulation of the case herein discussed, abrupt blood pressure elevations occurred, which were controlled with adenosine. Various drugs have been used during management of hypertensive crises. (5)

Due to its favorable pharmacokinetic profile, nitroglycerine and nitroprussiate have been considered two essential drugs for the management of hypertensive crises. Nitroprussiate has a fast onset of action, its clinical effect fades away in 1 to 3 minutes and produces less reflex tachycardia than nitroglycerine. However, high doses may result in thiocyanate toxicity and give rise to severe complications. (10,11) Calcium-antagonists have a lower preload reduction, less episodes of hypotension during the initial titration and less tachycardia. However, their duration of action is between 3 to 6 hours. Clevidipine has been available over the last few years, as an alternative for fast hemodynamic control. With a half-life of around 1 minute and of 15 minutes in its end-stage, has as major disadvantages the ability to cause reflex tachycardia and requires between 2 to 4 minutes to reach a balanced hypotensive effect. Magnesium sulphate, notwithstanding its beneficial effects in patients with arrhythmia or cardiac dysfunction, interacts with multiple frequently used drugs by potentiating their effect; such is the case of neuromuscular blockers, hypnotic agents, and opiates. Urapidil is a short-acting α -antagonist with central hypotensive effect, while β -blockers such as esmolol and labetalol, have a reduced desired effect in case of a hypertensive crisis, following adequate preoperative antihypertensive therapy. Furthermore, the use of β -blockers is limited in patients with cardiac dysfunction. (12-14)

Adenosine in continuous perfusion is highly effective due to its extra-short acting time of 10 to 40 seconds and to the on-off phenomenon associated with a plasma half-life of less than 10 seconds, in addition to the cell surface adenosine A₁ and A₂ purinic receptors activator effect, which results in smooth muscle relaxation

due to inhibition of the calcium inflow and adenylyl cyclase activation. (12) All of this achieves a potent dose-dependent, fast-reversal arterial vasodilator effect. Furthermore, adenosine is a potent anti-arrhythmic that suppresses adrenaline-associated ventricular ectopy and is a safe and effective coronary vasodilator. Neither does it cause tachyphylaxis or hypertensive rebound upon discontinuation.

Keeping in mind that adrenaline and noradrenalin half-life in blood is extremely short and their release during pheochromocytoma surgery is episodic and circumscribed, particularly to the periods of tumor manipulation, it could be considered a safe drug for the management of pheochromocytoma.

The case herein described highlights the importance of adequate preparation and preoperative optimization of patients with pheochromocytoma. Adenosine allowed for a rapid treatment of the hypertensive crises that developed during the tumor manipulation, maintained the patient's hemodynamic stability and enabled a safe extraction. Patients pending surgery with recent SARS-CoV-2 infection, should be individualized.

ETHICAL RESPONSIBILITIES

Endorsement by the Ethics Committee

This study was approved by the Ethics Committee of the Hospital Universitari Vall d'Hebron, on January 29, 2021, for research project number PR(AG)671/2020.

Protection of persons and animals

The authors declare that no experiments in humans or animals were conducted for this research. The authors declare that the procedures followed are consistent with the ethical standards of the responsible

human experimentation committee, and in accordance with the World Medical Association and the Declaration of Helsinki.

Confidentiality of the data

The authors hereby declare that they followed the protocols of their work institution regarding the publication of patient data.

Right to privacy and informed consent

The authors declare that no patient data were disclosed in this article. The authors obtained the informed consent of the patient and/or subject referred to in the article. This document is in the possession of the corresponding author.

ACKNOWLEDGEMENTS

Contributions by authors

MAA: Planning of the study, gathering of data, interpretation of the results and initial drafting of the manuscript.

VMA and YLA: Planning of the study, gathering of data, interpretation of the results, analysis of the data and final drafting of the manuscript.

MMN, OMS and ACR: Conception of the original project, planning of the study, interpretation of the results, drafting and final approval of the manuscript.

Assistance for the study

None declared.

Financial support and sponsorship

None declared.

Conflict of interests

None declared.

Presentations

None declared.

Acknowledgement

To the Endocrine, Metabolic and Bariatric surgery team of our Center for their close collaboration and constant communication as part of the interdisciplinary team.

REFERENCES

1. Naranjo J, Dodd S, Martin Y. Perioperative management of pheochromocytoma. *J Cardiothorac Vasc Anesth.* 2017;31(4):1427-39. doi: <https://doi.org/10.1053/j.jvca.2017.02.023>.
2. Pisarska M, Pędzwiatr M, Budzyński A. Perioperative hemodynamic instability in patients undergoing laparoscopic adrenalectomy for pheochromocytoma. *Gland Surg.* 2016; 5(5):506-11. doi: <https://doi.org/10.21037/ggs.2016.09.05>.
3. Neumann HPH, Young WF Jr, Eng C. Pheochromocytoma and paraganglioma. *N Engl J Med.* 2019;381(6):552-65. doi: <https://doi.org/10.1056/NEJMra1806651>.
4. Lafont M, Fagour C, Haissaguerre M, Darrancette G, Wagner T, Corcuff JB, Tabarin A. Per-operative hemodynamic instability in normotensive patients with incidentally discovered pheochromocytomas. *J Clin Endocrinol Metab.* 2015;100(2):417-21. doi: <https://doi.org/10.1210/jc.2014-2998>.
5. Ramakrishna H. Pheochromocytoma resection: Current concepts in anesthetic management. *J Anaesthesiol Clin Pharmacol.* 2015;31(3):317-23. doi: <https://doi.org/10.4103/0970-9185.161665>.
6. Cucinotta D, Vanelli M. WHO Declares COVID-19 a pandemic. *Acta Bio-med.* 2020;91(1):157-60. doi: <https://doi.org/10.23750/abm.v91i1.9397>.
7. Casey RT, Valk GD, Schalin-Jäntti C, Grossman AB, Thakker RV. Endocrinology in the time of COVID-19: Clinical management of neuroendocrine neoplasms (NENs). *Eur J Endocrinol.* 2020;183(2):G79-G88. doi: <https://doi.org/10.1530/EJE-20-0424>.
8. Gubbi S, Nazari MA, Taieb D, Klubo-Gwiedzinska J, Pacak K. Catecholamine physiology and its implications in patients with COVID-19. *Lancet Diabetes Endocrinol.* 2020;8(12):978-86. doi: [https://doi.org/10.1016/S2213-8587\(20\)30342-9](https://doi.org/10.1016/S2213-8587(20)30342-9).
9. COVID Surg Collaborative; GlobalSurg Collaborative. Timing of surgery following SARS-CoV-2 infection: an international prospective cohort study. *Anaesthesia.* 2021. doi: <https://doi.org/10.1111/anae.15458>.
10. Nottebaum BJ, Groeben H. Anästhesiologisches Management bei Phäochromozytomoperationen. *Urologe.* 2016;55:723-31. doi: <https://doi.org/10.1007/s00120-016-0082-9>.
11. Ubré M, García M, Pujol R, et al. Implicaciones anestésicas de la patología suprarrenal y cirugía de las suprarrenales y de la hipófisis. En: Gomar C, Villalonga A, Castillo J, Carrero EJ, et al. Formación continuada en anestesiología y reanimación. 1ª Edición. Madrid: Ergon; 2020. pp. 878-90.
12. Agencia Española del Medicamento y Productos Sanitarios. Fichas técnicas de medicamentos [internet]. 2020 [cited: 2021 mar. 12]. Available at: https://cima.aemps.es/cima/dochtml/ft/36189/FT_36189.html
13. Lord MS, Augoustides JG. Perioperative management of pheochromocytoma: focus on magnesium, clevidipine, and vasopressin. *J Cardiothorac Vasc Anesth.* 2012;26(3):526-31. doi: <https://doi.org/10.1053/j.jvca.2012.01.002>.
14. Buch J. Urapidil, a dual-acting antihypertensive agent: Current usage considerations. *Adv Ther.* 2010;27(7):426-43. doi: <https://doi.org/10.1007/s12325-010-0039-0>.