

Case report: treatment of pancreatic pseudocysts with endoscopic transpapillary drainage

Rómulo D. Vargas, MD,¹ Mauricio Sepúlveda-Copete, MD,² Julio E. Zuleta, MD,² Albis C. Hani, MD.¹

¹ Internist and Gastroenterologist, Gastroenterology Unit, Hospital Universitario San Ignacio. Pontificia Universidad Javeriana. Bogotá, Colombia.

² Internist and Fellow of Gastroenterology and Digestive Endoscopy, Hospital Universitario San Ignacio. Pontificia Universidad Javeriana. Bogotá, Colombia.

Received: 15-05-10

Accepted: 26-05-10

Abstract

We report on the case of a patient with pancreatic pseudocysts. They presented as complications of an episode of acute pancreatitis which had manifested as epigastric pain, vomiting, and a postprandial sensation of fullness. After 12 months of watchful waiting the patient had not improved. Instead, an abdominal CAT scans revealed that the lesion persisted and had grown an additional 4 cm in diameter. The patient was referred to our institution for treatment. A magnetic resonance cholangiopancreatography (MRCP) image revealed that the pseudocyst passed through the proximal pancreatic duct. Endoscopic transpapillary drainage was successfully performed with the insertion of a pancreatic stent. The lesion had disappeared 30 days after drainage. Symptoms had not recurred 60 days after drainage.

Key words

Pancreatic pseudocysts, endoscopic transpapillary drainage, acute pancreatitis.

CASE REPORT

A 54 year old male patient was referred to gastroenterology. Two years earlier he had had acute pancreatitis following blunt trauma.

Three months after the acute pancreatitis the patient began to present dull upper abdominal pain that was exacerbated by food intake associated with vomiting. An abdominal CT scan was requested. It showed a pancreatic pseudocyst of 2.8cm x 3cm x3.1 cm located in the body of the pancreas. Expectant management and clinical observation were decided upon.

However, after six months the patient's pain had persisted and intensified. It was associated with vomiting and postprandial fullness. Another CT scan was performed. It showed that the pancreatic pseudocyst had grown to a size of 3cm x 4cm x 3.5cm. The patient continued under medical care, taking hyoscine butylbromide and acetaminophen for pain with partial relief of symptoms.

The physical examination during the patient's check-up showed epigastric pain with positive bowel sounds upon palpation. No masses were evident during palpitation. The patient had no fever or tachycardia. His weight was 65 kg and his body mass index was 23.8.

The complete blood count showed leukocytes, hemoglobin and platelets all within normal limits.

SPatient underwent magnetic resonance cholangiopancreatography (MRCP). It showed a unilocular cystic lesion in the body of the pancreas in continuity with the main pancreatic duct. Its dimensions were 3.7cm x3.0cm x 4.1 cm which is consistent with a pseudocyst (Figure 1).

Based on these findings we considered that the patient was suffering from a symptomatic pancreatic pseudocyst two years after an episode blunt trauma. The unilocular pseudocyst was located in the body of the pancreas in contact with the pancreatic duct. It was less than 6 cm in size. This patient was a candidate for endoscopic transpapillary drainage to manage his pseudocyst.

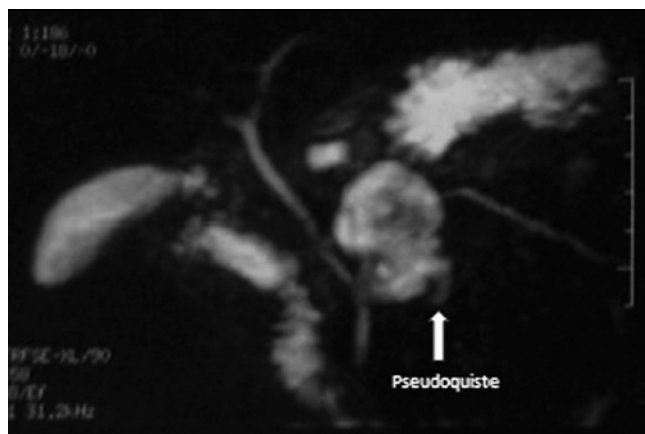


Figure 1. Magnetic resonance cholangiography. Normal bile duct. Pseudocyst communicated with the pancreatic duct.

Endoscopic retrograde cholangiopancreatography (ERCP) was performed on the patient. It showed stenosis of the common bile duct. The pancreatic duct pseudocyst was catheterized and opacified. Opacification of the pseudocyst was observed (Figure 2). A pancreatic sphincterotomy was performed followed by insertion of a 5 French x 5 cm plastic stent in the proximal end of the pseudocyst. Pancreatic fluid drainage showed at the distal end of the stent (Figure 3). The bile duct was found to be normal.

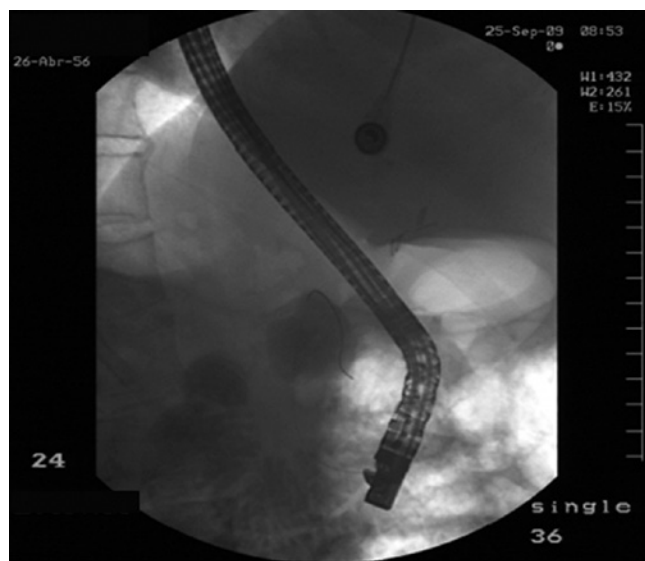


Figure 2. ERCP. Pancreatography. Hydrophilic guide wire inside the pseudocyst.

At the two week check-up after stent insertion the patient showed significant clinical improvement with decreased pain and increased oral tolerance. The abdominal ultrasound showed evidence of diminution of the pseudocyst's

size to 2cm x 1cm x 1cm. We decided to remove the pancreatic stent.

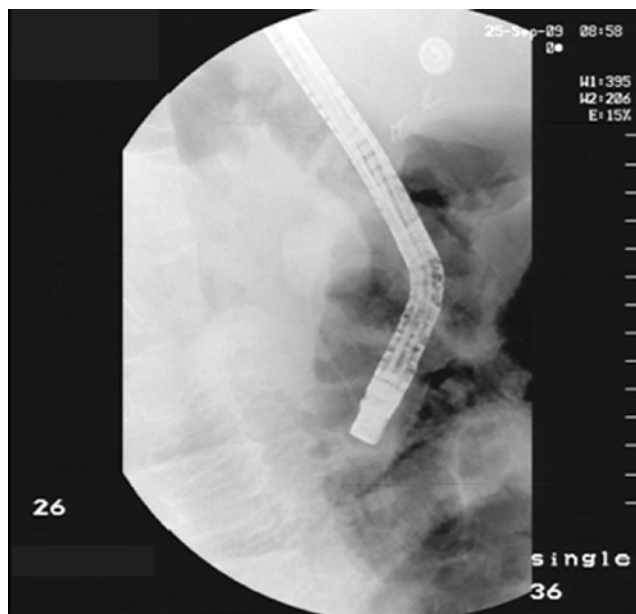


Figure 3. ERCP. Pancreatography. 5Fr stent draining the pseudocyst.

Additional tests were conducted. 30 days after stent insertion. The patient had none of the symptoms for which he had initially been referred. The cyst could not be seen in a sonogram. At the 60 day follow up the patient remained asymptomatic.

DISCUSSION

A pancreatic pseudocyst is a collection of fluid which is rich in amylase and other pancreatic enzymes. It is which is covered by a wall of fibrous tissue which is not surrounded by epithelium (1). A pancreatic pseudocyst is caused by disruption of the pancreatic duct followed by an increase in ductal pressure caused by stenosis, stones, precipitation of proteins which block the pancreatic duct proximal, or as the result of pancreatic necrosis after an episode of acute pancreatitis. They connect to the pancreatic duct either directly or through the pancreatic parenchyma (2).

The main causal factors in pancreatitis are alcoholism, biliary etiology, and then abdominal trauma (3).

There are several classifications of pancreatic pseudocysts. One of them is the Nealon and Walser classification system which is based on the anatomy of the pancreatic duct (4). Type I indicates a normal duct with no connections to the cyst. Type II is a normal duct connected to the cyst. Type III indicates a duct with stenosis that is

not connected to the cyst. Type IV indicates a duct with stenosis that is connected to the cyst. Type V indicates a duct with complete obstruction. Type VI indicates chronic pancreatitis without any connection between duct and cyst. Type VII indicates chronic pancreatitis with the duct connected to the cyst. This classification can also provide a guide to physicians about the best type of approach for the treatment of pseudocysts (surgical, endoscopic and/or percutaneous drainage).

More than 50% of pseudocyst cases resolve spontaneously, consequently it is considered that the initial management of patients should consist of hydration, analgesics and antiemetics (5-10). The two main factors determining spontaneous regression of pancreatic pseudocysts are size and time of evolution after diagnosis (11). Significant numbers of pseudocysts of less than 4cm resolve spontaneously. Moreover, they have lower complication rates than do larger cysts (1, 6-11). In relation to time, acute pseudocysts have a higher rate of spontaneous regression in the first 6 weeks after observation than do pseudocysts which have persisted more than 7 weeks after diagnosis (8%). Relative indications for whether or not spontaneous regression will occur include pseudocyst sizes larger than 4 cm and no changes in size, morphology, or progression after an observation period of 6 weeks (1).

Symptomatic pseudocysts are those with complications. Complications including infections, hemorrhaging, compression of large vessels, obstruction of gastric outflow tract and obstruction of biliary duct are the main indications for drainage. The choice of management depends on local experiences. However, endoscopic treatment is preferred because it is a less invasive method than surgery. It avoids the need for external drainage and has a high long-term success rate. Transpapillary drainage can be performed with ERCP or direct drainage is possible through the stomach or duodenal walls. Endoscopic ultrasonography (EUS) is considered to be the test of choice for determination of the size and location of the pseudocyst and for measurement of wall thickness.

Transgastric or transduodenal endoscopic drainage is indicated in cases of simple mature pseudocysts where there has been no disruption of the pancreatic duct. Ideally they should be larger than 5 cm and be producing compression in the gastric or duodenal wall. The distance between the pseudocyst and the gastric or duodenal wall duodenal should be less than 1 cm (11). This distance can be measured adequately by EUS.

Transpapillary drainage through pancreatic stent insertion is indicated when the pseudocyst is connected to the pancreatic duct. It can be successful for patients with pancreatic duct disruption (3). Individual reports have found

that the pancreatic pseudocyst is connected to the pancreatic ductal system in 22% to 57% of cases (7, 9).

No randomized prospective studies have been published which would provide answers to questions about the necessary duration of treatment with pancreatic duct stents, the optimal timing of stent insertion, or how often stents should be changed.

Barther et al reported that, in a number of cases, the duration of therapy depends on the pseudocyst regression time. The mean time in published studies was 4.4 months (7). Catalano et al. performed a study on 37 patients. For 17 patients, resolution was immediate. 16 patients were free of recurrences at 37 months. The stents were replaced every 6-8 weeks if the pseudocysts remained unresolved (8).

In general, when the pseudocyst is less than 6 cm, and it is connected to the pancreatic duct, there is a better than 90% success rate with complete resolution of the lesion through transpapillary drainage (10).

At present, transcutaneous drainage is indicated only as an emergency procedure in cases of acute retention of fluid or when cysts are infected. This is because this procedure had a rate of recurrence greater than 70% and because formation of percutaneous fistulas is a common complication.

The patient we are reporting on had a pseudocyst that was 4 cm in diameter and was connected to the main pancreatic duct. After insertion of the stent the lesion resolved in 4 weeks. It was completely resolved, without symptoms and without recurrence, by the 60 day check-up.

Our conclusion is that the current trend in managing pancreatic pseudocysts with minimally invasive therapeutic and endoscopic procedures is superior to surgical procedures in terms of morbidity and mortality rates, however these procedures cannot always be performed. In making decisions about the treatment of pancreatic pseudocyst it is important to note that about 50% do not require intervention and resolve spontaneously with observation and clinical follow-up (10).

The selection of a technique for pseudocyst drainage depends on the experience of the group treating the pseudocyst. Transpapillary drainage is a safe and highly efficient option when the lesion is less than 6 cm, and it is connected to the pancreatic duct.

REFERENCES

1. Bradley EL 3rd. A clinically based classification system for acute pancreatitis. Summary of the International Symposium on Acute Pancreatitis, Atlanta, Ga, September 11 through 13, 1992. *Arch Surg* 1993; 128: 586-590.
2. Gumaste VV, Pitchumoni CS. Pancreatic pseudocyst. *Gastroenterologist* 1996; 4: 33-43.
3. Draganov PV. Pancreatic pseudocyst. *World J Gastroenterol* 2009; 15: 38-47.

4. Nealon WH, Walser E. Main pancreatic ductal anatomy can direct choice of modality for treating pancreatic pseudocysts (surgery versus percutaneous drainage). *Ann Surg* 2002; 235: 751-758.
5. Maringhini A, Uomo G, Patti R et al.: Pseudocysts in acute nonalcoholic pancreatitis: incidence and natural history. *Dig Dis Sci* 1999; 44: 1669-73.
6. Gouyon B, Levy P, Ruszniewski P et al.: Predictive factors in the outcome of pseudocysts complicating alcoholic chronic pancreatitis. *Gut* 1997; 41: 821-5.
7. Barthet M, Sahel J, Bodiou-Bertei C, Bernard JP: Endoscopic transpapillary drainage of pancreatic pseudocysts. *Gastrointest Endosc* 1995; 42: 208-1.
8. Catalano MF, Geenan JE, Schmalz MJ, Johnson GK, Dean RS, Hogan WJ. Treatment of pancreatic pseudocysts with ductal communication by transpapillary pancreatic duct endoprosthesis. *Gastrointest Endosc* 1995; 42: 214-8.
9. Sharma SS, Bhargawa N, Govil A: Endoscopic management of pancreatic pseudocyst: a longterm follow-up. *Endoscopy* 2002; 34: 203-7.
10. Baron TH. Endoscopic drainage of pancreatic pseudocysts. *J Gastrointest Surg* 2008; 12: 369-72.
11. Lerch M, Stier A, Wahnschaffe U, Mayerle J. Pancreatic Pseudocysts. *Dtsch Arztebl Int* 2009; 106: 614-21.