

Images of early gastric cancer: a series of cases

Martín Alonso Gómez, MD.¹

¹ Assistant Professor of Gastroenterology in the Internal Medicine Department at the Universidad Nacional de Colombia in Bogotá, Colombia

Received: 02-09-12
Accepted: 26-06-13

Abstract

This article presents a study of a series of 5 cases of early gastric cancer, which seeks to raise awareness among young gastroenterologists about the importance of early detection of cancer. It presents images of how these tumors were found and evaluated in our hospital. These 5 cases show each of the types of cancer according to the Paris classification through endoscopic images is shown, pathology, and how each case was treated. Some EUS images are also included.

Key words

Gastric cancer, endoscopic mucosal resection, endoscopic ultrasound.

In 1903 German physician M. Versé first described early gastric cancer in his book *Die Histogenese der Schleimhautcarcinome* (1), but the first to use the term early gastric cancer was the Frenchman Bayle in 1833 who called it “Gastric cancer in its early stages” (2).

This term is used for patients with gastric cancer whose tumors invade into the submucosa whether or not lymph nodes are compromised (3). The 5-year survival rate among these patients can reach almost 100% as our group recently demonstrated (4). However, advanced gastric cancer (muscularis propria) has dramatically reduced 5 year survival rates of less than 10% (5).

Gastric cancer is the second leading cause of cancer in men and the fourth leading cause in women in Colombia. It is the leading cause of cancer mortality according to the INC (2005) (6). 80% of these lesions are diagnosed in late stages with the dismal prognosis already noted. This makes prevention and detection of these tumors at an early stage a prime target in order to change this reality.

For endoscopic classification of tumors we use the Japanese classification system established in 1962, modified

by the Paris classification of 2003 (Figure 1) (7). For advanced cancer we use the Bormann classification (Figure 2).

In this paper we present the images of some of our patients with early cancer to illustrate each of the types described by the Paris classification. We not only show these tumors which are characterized as rare in our environment but also show their treatment.

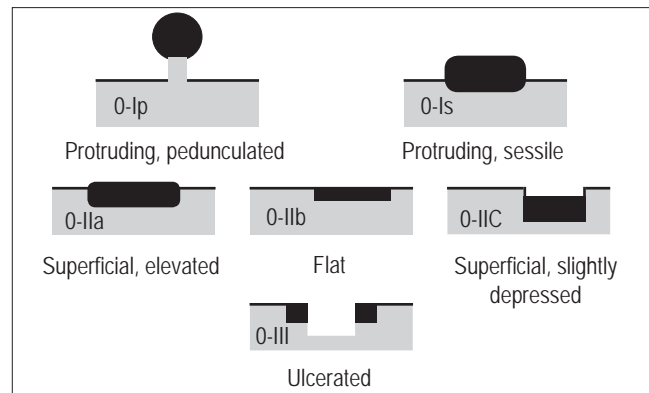


Figure 1. Paris classification of early gastric cancer.

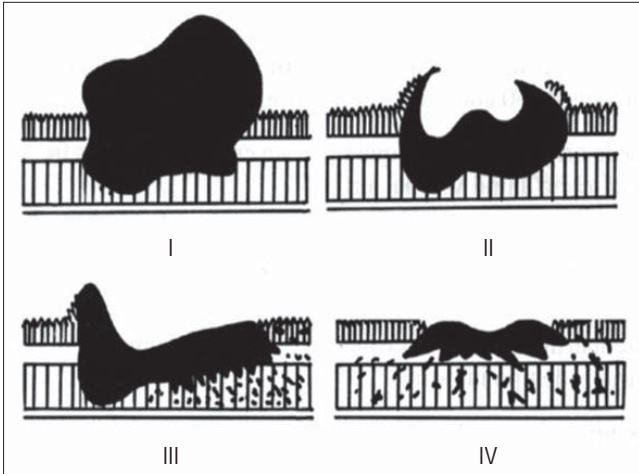


Figure 2. Borrmann classification of advanced gastric cancer.

CASE 1

Early gastric cancer 0-Ip

Upper endoscopy was performed on a 75 year old patient who had developed dyspeptic symptoms without any prior warning signs. A raised 20 mm lesion found in the prepyloric region was classified as a type 0-I lesion (Figure 3). Endoscopic mucosal resection performed with the lift and cut with loop method achieved complete removal without complications (Figure 4). A previous endoscopy had shown compromise by a tumor in only the first two ultrasound layers i.e. the mucosa (Figure 5). The pathology report indicated a well-differentiated adenocarcinoma with lateral edges and depths that were negative for a tumor (Figure 6).

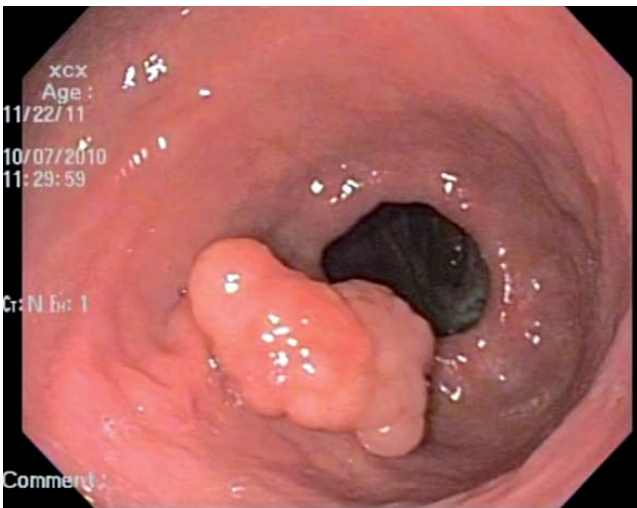


Figure 3. There is a clear raised polypoid lesion in the pyloric region.

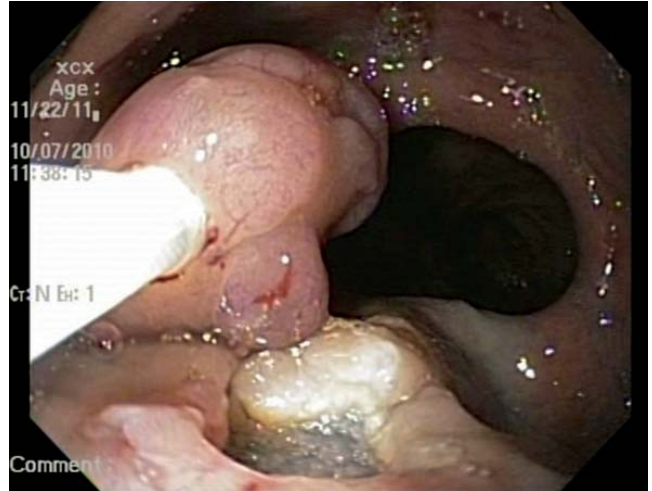


Figure 4. The lesion is excised by the injection method and loop removal. Note that the loop is trapping the excised lesion and at the bottom there is an evident residual ulcer.

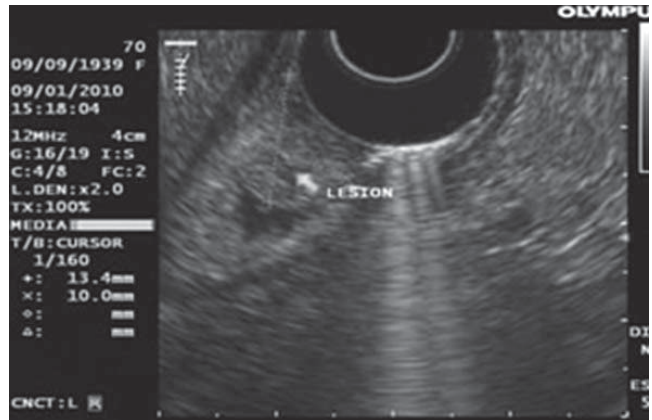


Figure 5. The arrow points to a hypoechoic lesion measuring 13.4cm in diameter which compromised only the mucosal layer.

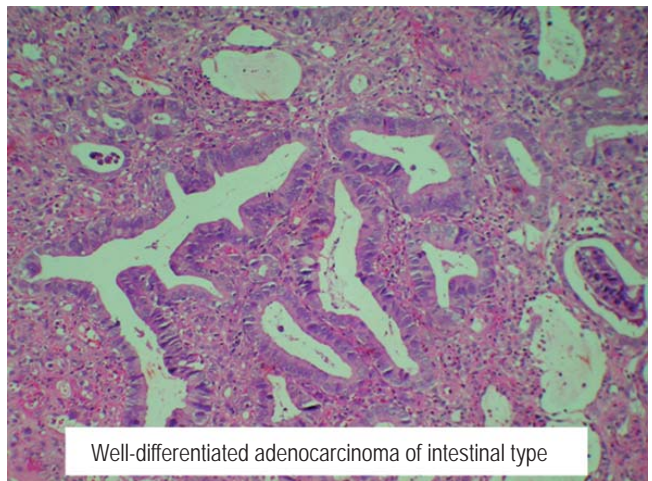


Figure 6. Irregular, tortuous glands that vary in size and which are infiltrated by tumor cells.

In this other case a raised lesion in the anterior wall of the mid-corpus (Figure 7) can be seen. It was reported as a well-differentiated adenocarcinoma. An endoscopy showed that the lesions compromised only the first two ultrasound layers (mucosa) (Figure 8).

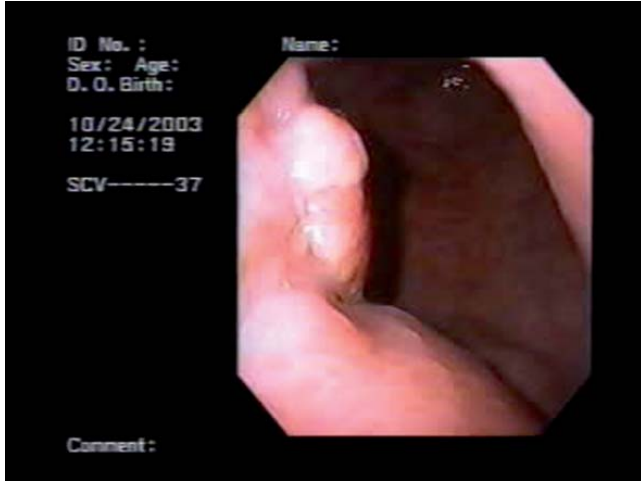

Figure 7. Raised lesion evidenced in the anterior wall.

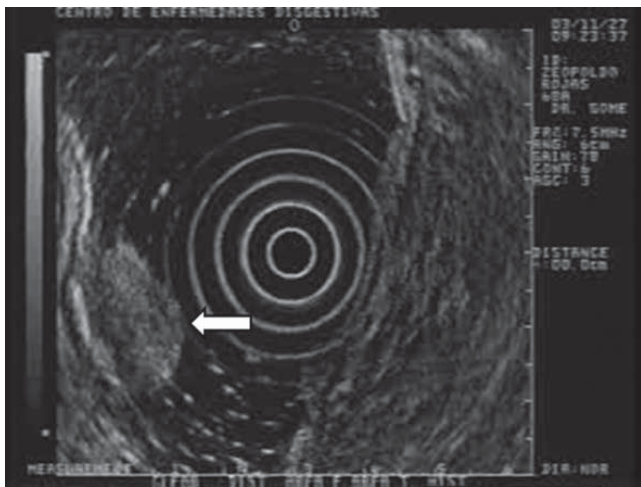


Figure 8. EUS evidences an isoechoic lesion infiltrating layers 1 and 2 of the mucosa (arrow).

CASE 2

Early gastric cancer 0-II a + II c

Endoscopy of a 45-year-old patient with dyspeptic symptoms without warning signs such as bleeding, weight loss or vomiting showed a raised lesion in the pre-pyloric antral region that appeared to be ulcerated in the center (Figure 9).

Chromoscopy with a mixture of 0.4% carmine indigo plus 15 ml of acetic acid (vinegar) to better characterize the lesion showed a raised lesion with a sunken center which

corresponds to a cancer type 0 - IIa + IIc (Figure 10). The biopsy confirmed diffuse cancer, so the patient was referred to surgery (Figure 11).

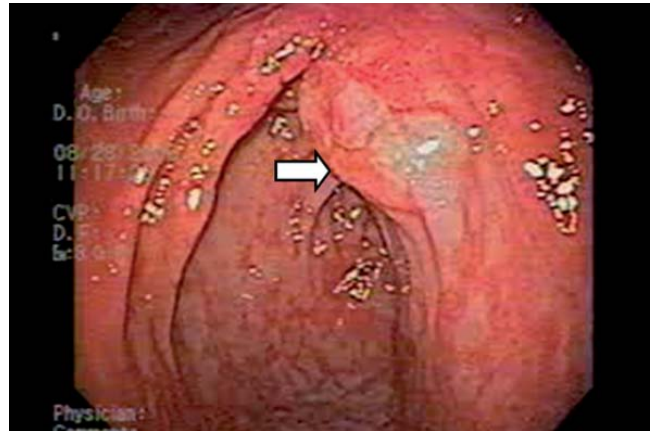


Figure 9. Observe the raised lesion which is sunken in the center in the prepyloric region of the lesser curvature.

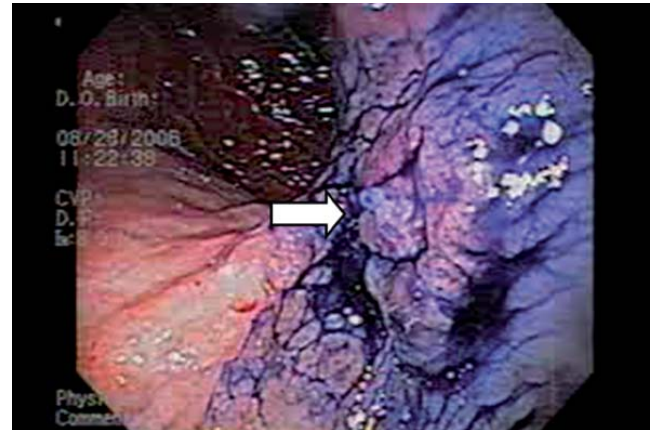


Figure 10. Chromoscopy allows significant enhancement of the lesion.

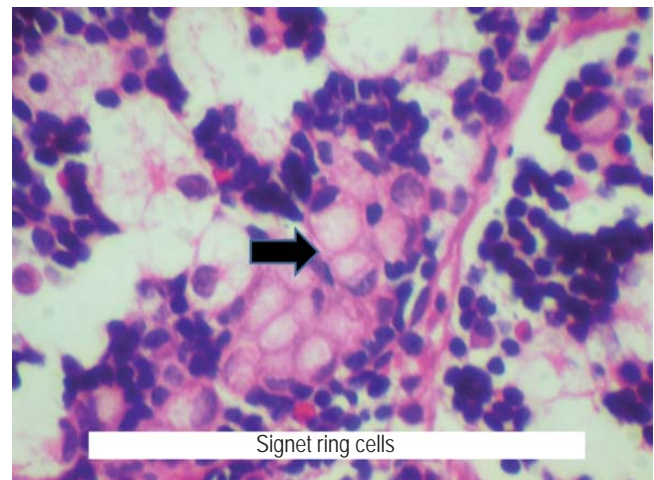


Figure 11. Diffuse cancer identified by the signet ring cells indicated by the arrow.

CASE 3

Early gastric cancer 0-II b

The first endoscopy of a 74-year-old patient who had suffered 6 years of evolving epigastric pain without bleeding or weight loss showed an erythematous lesion on the lesser curvature toward the gap (Figure 12). Chromoscopy using 0.4% indigo carmine achieved fine highlighting of the lesions' boundaries as shown in Figure 13. The lesion was classified as IIb lesion after biopsies showed that it was a moderately differentiated cancer (Figure 14). Mucosal resection was performed.

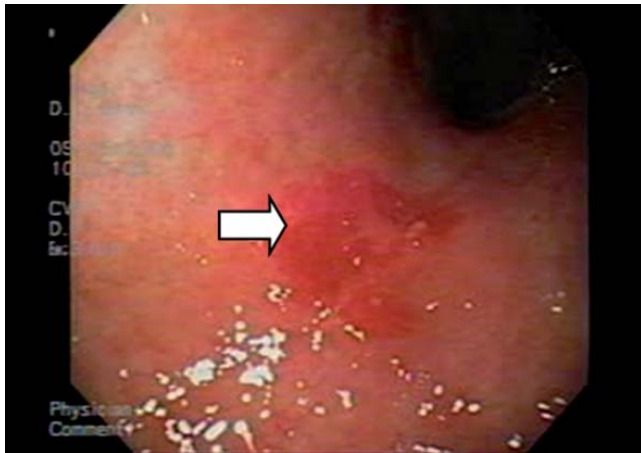


Figure 12. An erythematous lesion that shows no raised area under white light endoscopy.

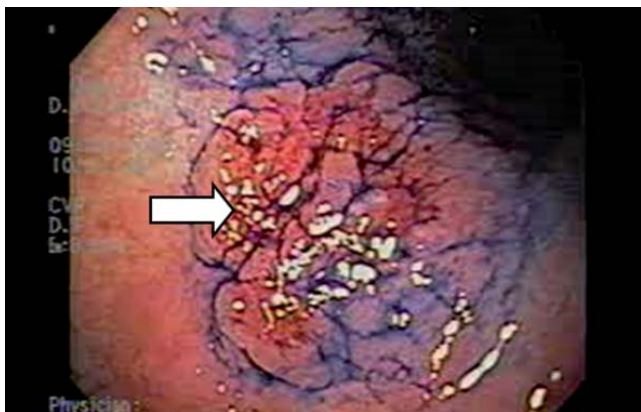


Figure 13. Chromoscopy allows delineation of borders of the lesion and resection.

CASE 4

Early gastric cancer 0- IIc

Endoscopic examination of a 66 year old patient with megaloblastic anemia revealed a lesion in the greater cur-

vature of the antrum. The lesion had convergent folds and was sunken in the center but had no atrophy (Figure 15). Chromoscopy with indigo carmine provided excellent definition of the lesion which allowed characterization as IIc (Figure 16). A biopsy confirmed that it was a moderately differentiated adenocarcinoma (Figure 17). In this other case there is a patient with a prepyloric sunken lesion reported as a poorly differentiated adenocarcinoma (Figure 18).

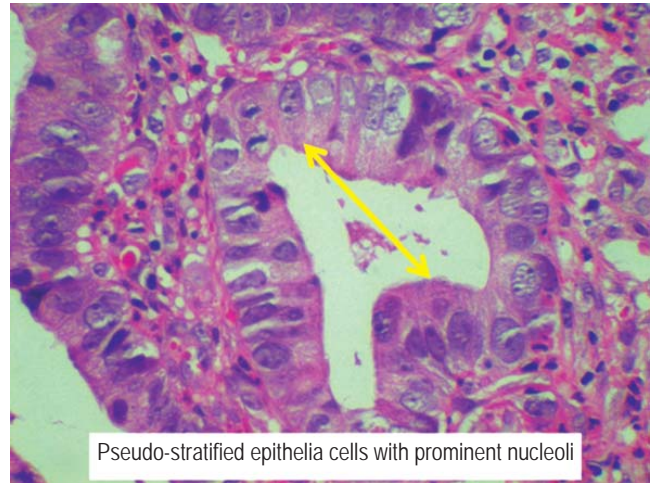


Figure 14. The arrow points to pseudo-stratified epithelium with prominent nucleoli consistent with moderately differentiated cancer.

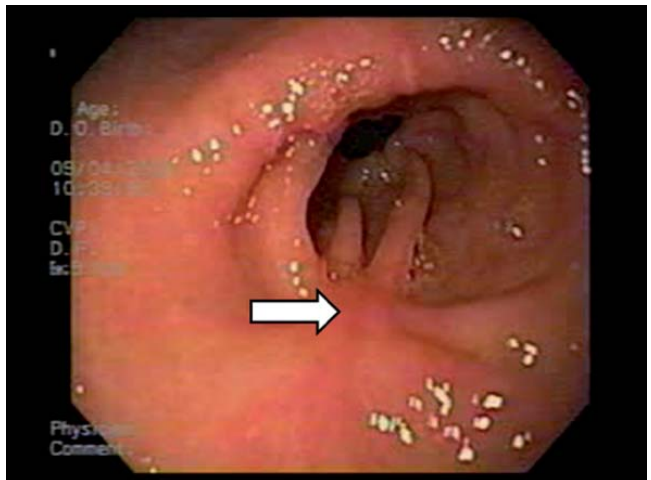


Figure 15. Notice a sunken lesion type IIc in the lower curve.

CASE 5

Early Gastric Cancer TYPE: 0 – III

Upper endoscopy of a 60-year-old patient admitted to the emergency room with hematemesis and melena, but without weight loss, showed a pre-pyloric ulcerated lesion with irregular borders which was covered with fibrin

(Figure 19). The lesion was diagnosed as a moderately differentiated adenocarcinoma (Figure 20), and the patient was referred to surgery which confirmed that the lesion extended into the submucosa.

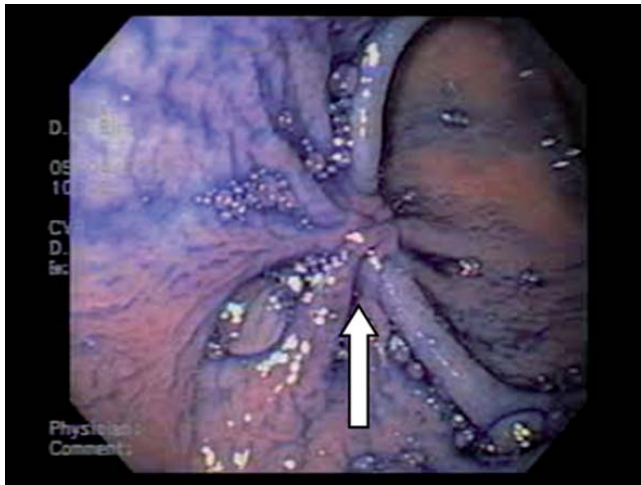


Figure 16. Chromoscopy shows that the lesion was bigger and had with convergent folds which are abruptly amputated.

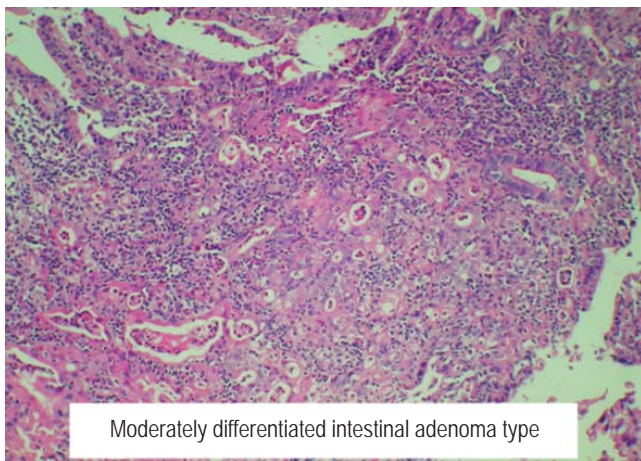


Figure 17. Hematoxylin eosin evidenced a moderately differentiated adenocarcinoma.

In conclusion, we can see that the early gastric cancer can be diagnosed and treated through upper endoscopy. Although most of the lesions described were small and were resolved through mucosal resection, we consider that, despite the proliferation of techniques, submucosal dissection will become the standard therapy for these tumors (8-11). On the other hand, even though in our service approximately 20% of cases of gastric cancer are detected in early stages, we are still far from reaching the 60% figures (12) of Japanese series. Nevertheless, we believe that with screening, training of gastroenterologists, and motivation for detection of these lesions we can reach these figures.

This would radically change the burden of this disease in our environment.

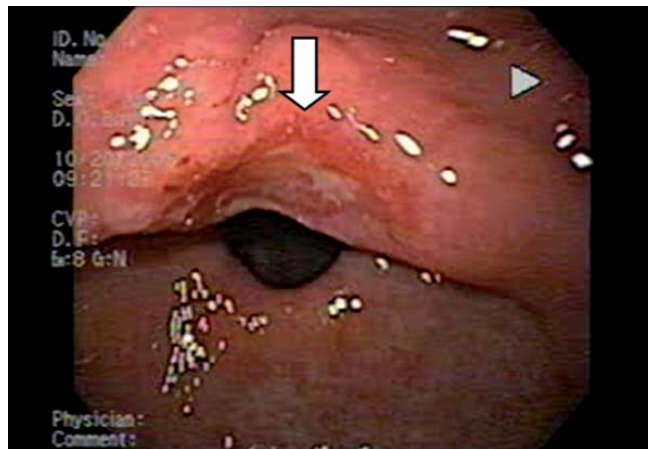


Figure 18. Central sunken lesion with ill-defined borders located in the pyloric region.

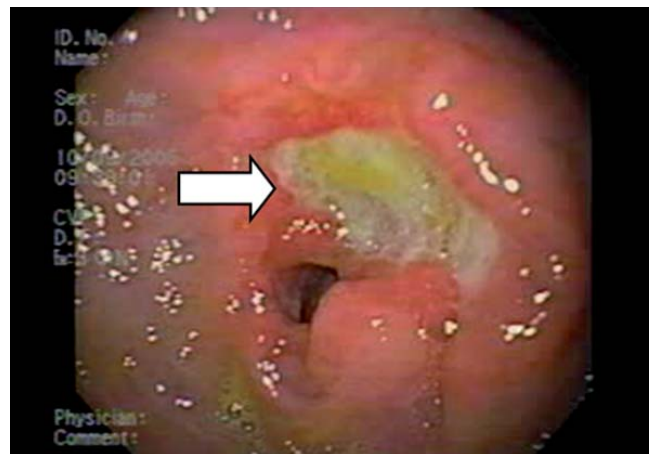


Figure 19. An ulcerated lesion covered with fibrin with raised and irregular borders.

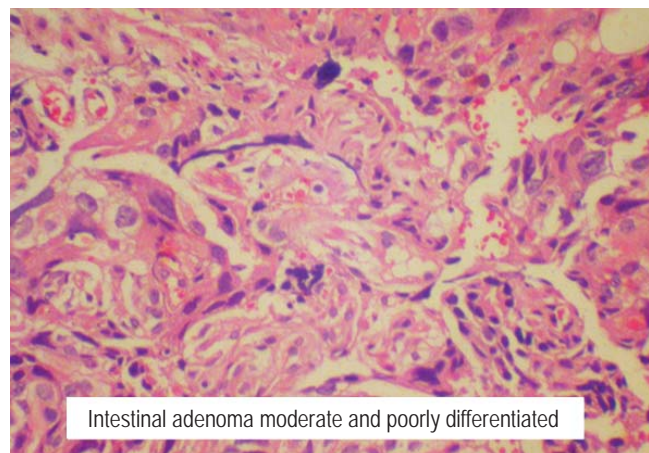


Figure 20. The image indicates a poorly differentiated tumor with moderately differentiated tissue components.

REFERENCES

1. Hauser G. Das chronische Magengeschwür, sein Verarbeitungsprozess und dessen Beziehungen zur Entwicklung des Magenkarzinoms. Leipzig: FCW Vogel; 1883.
2. Versé M. Über die Entstehung, den Bau und das Wachstum der Polypen, Adenome und Karzinome des Magen-Darmkanals. *Arch Pathol Inst Leipzig* 1908; 1: 40.
3. Japanese Gastric Cancer Association. Japanese classification of gastric carcinoma. 2nd English ed. Tokyo: Kanehara; 1998.
4. Gómez M, Otero W, Arbeláez V. Tratamiento endoscópico de cáncer gástrico temprano en Colombia con seguimiento a cinco años. *Rev Col Gastroenterol* 2009; 24: 347-352.
5. Tsukuma H, Ohshima A, Narahara H, et al. Natural history of early gastric cancer: a non-concurrent, long-term, follow-up study. *Gut* 2000; 47: 618-621.
6. Piñeros M, Ferlay J, Murillo R. Incidencia estimada y mortalidad por cáncer en Colombia. Instituto Nacional de Cancerología; 2005.
7. Ohshiba S, Ashiba K, Tanaka M, et al. Curative endoscopic resection of early gastric cancer: the possibility of extending its indications. *Stomach Intest* 1993; 28: 87-98.
8. Rembacken BJ, Gotoda T, Fujii T, et al. Endoscopic mucosal resection. *Endoscopy* 2001; 33: 709-718.
9. Soetikno R, Gotoda T, Nakanishi Y, et al. Endoscopic mucosal resection. *Gastrointest Endosc* 2003; 57: 567-579.
10. Soetikno R, Kaltenbach T, Yeh R, et al. Endoscopic mucosal resection for early cancers of the upper gastrointestinal tract. *J Clin Oncol* 2005; 4490-4498.
11. Gotoda T. Endoscopic resection of early gastric cancer. *Gastric Cancer* 2007; 10: 1-11.
12. Yamashita K, Sakuramoto S, Nemoto M, Shibata T, Mieno H, Katada N, Kikuchi S, Watanabe M. Trend in gastric cancer: 35 years of surgical experience in Japan. *World J Gastroenterol* 2011; 17(29): 3390-7.