A Case Report of Hereditary Hemorrhagic Telangiectasia (HHT)

Martín Alonso Gómez, MD[1], Oscar Fernando Ruiz, MD[2], William Otero, MD[3]

1 Associate Professor Gastroenterology, Faculty of Medicine at the National University of Colombia. Gastroenterologist Hospital El Tunal, UGEC. Bogotá, Colombia
2 Gastroenterologist, Internist, National University of Colombia. Gastroenterologist UGEC and Hospital El Tunal. Bogotá, Colombia
3 Medicine Professor, Gastroenterologist. Gastroenterology Unit, National University of Colombia. Bogotá, Colombia

Received: 26-02-15
Accepted: 20-10-15

Abstract

Hereditary hemorrhagic telangiectasia (HHT) (also known as Osler Weber Rendu syndrome (OWRS)) is a rare dominant autosomal disorder whose frequency is between 1 per 1,331 people and 1 per 16,300 people depending on the population and its geographical location. There are no differences between genders. It is clinically characterized by telangiectasia, recurrent epistaxis, visceral vascular lesions (arteriovenous malformations - AVMs). Usually a person with HHT has a family history of the disorder. This paper reports a case that is clinically compatible with this rare entity and which presented simultaneous complications of pulmonary and cerebral abscesses.

Keywords

Telangiectasia, Osler Weber Rendu syndrome, hemorrhage.

CLINICAL CASE

A 62 year old man was admitted to our hospital following multiple episodes of hematemesis that had resulted in anemia requiring transfusion. Esophagogastroduodenoscopy revealed oropharyngeal, gastric and duodenal angiodysplasias. The patient had a history of heavy alcoholism, but reported no bleeding or transfusions. He had had no previous surgical procedures and had no family history related to his condition (Figure 1).

A physical examination upon admittance showed that the patient was cognitively impaired as evidenced by disorientation and right hemiparesis. He had been bedridden for 10 days prior to admission. During three days of hospitalization the patient presented peaks of fever, dyspnea and progressive deterioration until respiratory failure required ventilation support in the intensive care unit. Pneumonia was diagnosed (Figure 2) and then a lung abscess (Figure 3) was diagnosed.

An esophageal sonogram was done for differential diagnosis of infectious endocarditis. It a left ventricle ejection fraction of 55%and no evidence of valve disease or vegetation. As part of a multiple treatment scheme, the patient was given a cocktail of broad spectrum antibiotics consisting of ampicillin sulbactam, piperacillin-tazobactam and cefepime. Nevertheless, the patient continued to deteriorate until he developed severe sepsis and entered a persistent vegetative state. A CT scan of the brain (Figure 4) showed cerebral abscesses and an infectious process which required ventriculostomy to allow drainage through a catheter to relieve intracranial pressure. Finally, due to prolongation of ventilation support, the patient required a tracheostomy. Nevertheless, the patient's torpid state continued, and he died soon after.

HEREDITARY HEMORRHAGIC TELANGIECTASIA

The HHT or Osler-Weber-Rendu syndrome was initially described by Sutton in 1864 as a disorder characterized by

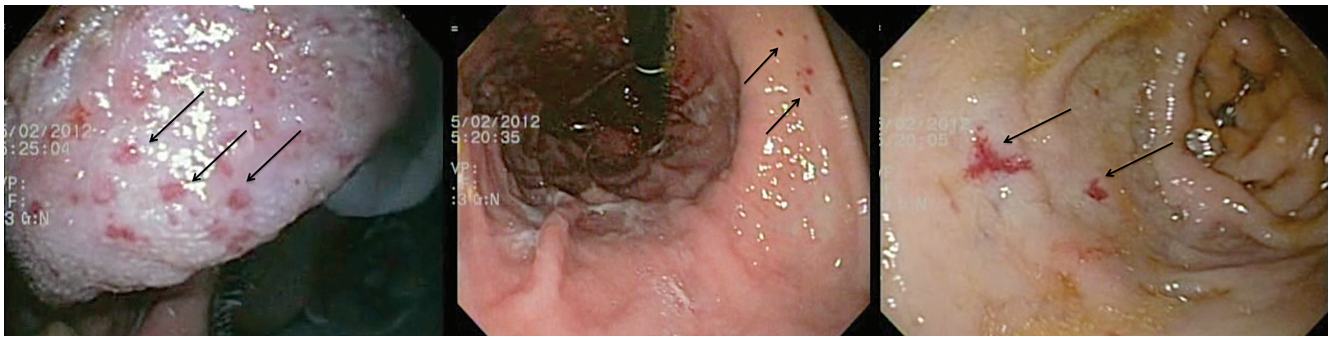

Figure 1. Esophagogastroduodenoscopy showing multiple angiodysplasia in the oral mucosa, gastric corpus and duodenum.

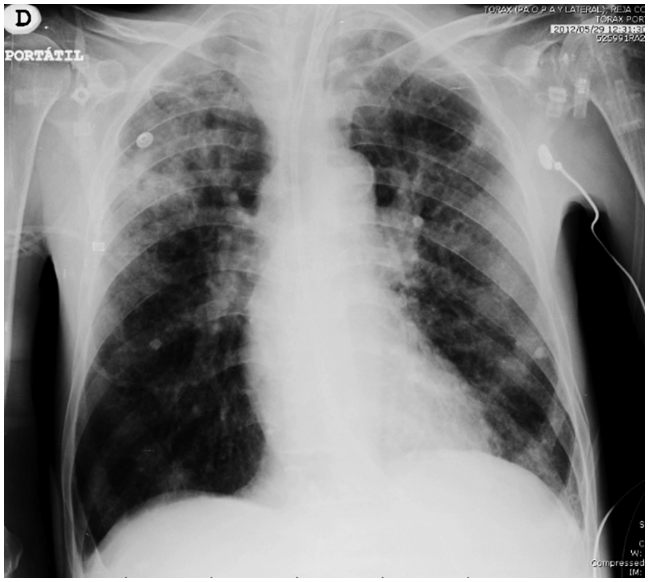

Figure 2. Chest X-ray showing alveolar infiltrates at the upper right with suspected community-acquired pneumonia.

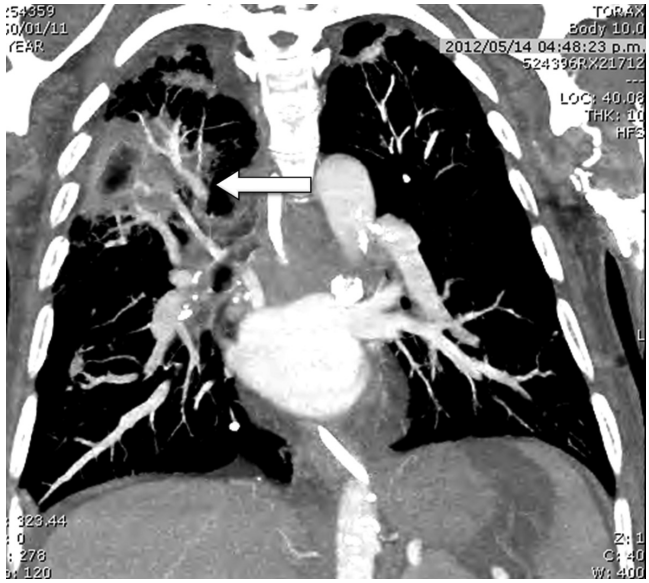

Figure 3. Chest CT scan compatible with lung abscess.

epistaxis and a "malformation of the vascular system" (1). Benjamin Guy Babington later described it as a "hereditary epistaxis" referring to family involvement (2). Then, in 1896, Rendu described it as an entity other than hemophilia (3). In 1901 Osler established its hereditary character and reported the presence of visceral arteriovenous malformations (4). In 1907, Weber published the first series of cases (5). The eponym of this disorder is taken from the names of these last three authors. It was universally accepted until 1909 when Hanes provided the term "hereditary hemorrhagic telangiectasia (HHT)" which is equally valid for practical purposes (6).

From an epidemiological point of view, there are no differences in the prevalence of HHT in terms of gender, but there is wide variation geographically. In general it varies from one to three cases per 500 to 5000 inhabitants in the western hemisphere (7).

Specifically in the USA, prevalence in Vermont is estimated at 1/16,500. In France, prevalence is 1/2,351, in northern England it is 1/39,216, and in Germany it is about 1/100,000 (8). The greatest prevalence has been found in the Curacao and Bonaire region where it has been reported in up to 1/1,331 inhabitants.

It is known that HHT has an autosomal dominant trait but that expression varies. At least five mutations in genes that can cause HHT have been identified. These genes encode proteins that modulate the activity of the transforming growth factor beta (TGF)-b signaling superfamily in vascular endothelial cells that regulate cell proliferation, differentiation, migration and extracellular matrix formation.

Figure 4. CT scan of the brain shows abscess in the left hemisphere.

According to their effects, five 5 different subtypes are recognized (Table 1). The two most frequent account for more than 80% of HHT. Hereditary hemorrhagic telangiectasia type 1 (HHT1 - MIM # 187300) results from a mutation in the gene encoding endoglin (ENG; 131195) on chromosome 9. Hereditary hemorrhagic telangiectasia type 2 (HHT2 - MIM # 600376) results from a mutation in the gene ACVRL1 which encodes activin receptor-like kinase 1 (ALK-1). A small proportion of HHT cases are due to a mutation in the MADH4 gene (Smad4, MIM # 175050) as part of an overlap syndrome of juvenile polyposis-HHT (10).

Table 1. Genetics of hereditary hemorrhagic telangiectasia

HHT Types	GEN	Chromosomal Locus
HHT 1	Endoglin or ENG	9q34.1
HHT 2	Activin Receptor-like Kinase 1, (ACVRL1/ALK 1)	12q11 - q14
HHT 3	-	5q31.3 - q32
HHT 4	-	7p14
HHT + juvenile polyposis coli	MADH4 or SMAD4	18q21.1
HHT 2 + primary pulmonary hypertension	BMPRII	2q33

Taken from (13)

ENG and ALK-1 mutations lead to production of unstable proteins with insufficient biological activity to reach the surface of the membrane or result in only small amounts of functionally useful endoglin or ALK-1. As a consequence, multiple changes occur. These include cell division dysfunction which limits angiogenesis and altered cell migration which limits three dimensional configuration of tubular structures needed in angiogenesis. In addition there is an alteration of the cytoskeleton since polymerization of actin filaments changes and this leads to a decrease in the cellular resistance of the vascular endothelium. This in turn causes premature lysis of endothelial cells of the capillaries when they are subjected to stress due to increased pressure or trauma (11).

Currently, the possible functions of vascular endothelial growth factor (VEGF) are being studied. High levels of VEGF together with TGF beta 1 have been found in patients with HHT, but at the moment it is not known whether these levels are causes or results of HHT (10).

From the histopathological point of view, HHT is characterized by damage to the walls of arterioles, venules and capillaries (which are the thinnest), decreased elastofibrosis and decreased thickness of the smooth muscle layer. This results in dilation of the vascular lumen and arteriovenous malformations which predispose blood vessels to rupturing. There are three patterns of vascular dysplasia in HHT: arteriovenous malformations in the lungs and brain (as occurred in our patient), telangiectasia (mucosa, dermis and visceral involvement) and pseudoaneurysms. Telangiectasias can be observed in all cases to one extent or another (7).

Pathogenesis, abnormal blood vessel formation and subsequent bleeding are all clinical manifestations of HHT. Although the number and location of lesions varies widely even within the same family, most telangiectasias are found in oral, nasal and gastrointestinal mucosa (Figure 1) while arteriovenous malformations (AVMs) are generally produced in the lungs, liver and central nervous system. These were present in our patient (Figures 2-4) and manifested themselves through gastrointestinal bleeding, lung abscesses and brain abscesses. It is not usual to see a case like this, and this is the first reported in Colombia as far as we know.

Smaller telangiectatic lesions usually present with symptoms of recurrent bleeding and secondary iron deficiency anemia. Other symptoms that can be seen in patients with larger AVMs are thrombosis and embolism (12, 13). Telangiectasias on the skin and mucous membranes, the presence of recurrent epistaxis, and a positive family history are the classic triad of HHT. An estimated 90% of patients with HHT have spontaneous and recurrent epistaxis, 75% have skin telangiectasia, 30% have pulmonary or hepatic impairment from AVMs, 15% have gastroin-

testinal bleeding, and 10-20% have CNS lesions (13-14). Progression of symptoms begins with epistaxis followed by pulmonary arteriovenous malformations (PAVMs) and later cutaneous and mucosal telangiectasia.

Brain abscesses and cerebrovascular incidents, as in our patient, are the direct result of PAVMs which cause short circuits on the left and right sides resulting in thrombosis ith shorts from right to left causing thrombosis and a paradoxical embolism. PAVMs should be regarded as a probable cause in patients with brain abscesses of unknown etiology. These complications may be the first manifestation of hereditary hemorrhagic telangiectasia (15-16).

Brain abscesses are the most severe neurological complication of PAVMs. They occur in 5% to 10% of patients with HHT (17). These brain abscesses have different clinical radiological and bacteriological characteristics from other entities. They are generally located in the superficial layers of the brain lobes, primarily in the parietal lobe, where micro-infarcts and septic embolism can occur. They are not commonly associated with staphylococcal infections but are rather associated with anaerobic microbes. They appear most often between the third and fifth decades of life as the number and size of PAVMs increase (17, 18).

In 2000, the Curacao diagnostic criteria were developed, and international diagnostic guidelines were published in 2009 (18, 19). They include the following points:

1. Spontaneous recurrent epistaxis at night
2. Mucocutaneous telangiectasia in characteristic places:
    - Lips
    - Tongue
    - Oral cavity
    - Nose
    - Soft tissues
3. Internal arteriovenous malformations
    - Lung
    - Brain
    - Liver
    - Gastrointestinal tract
    - CNS
4. Family history of HHT

Diagnosis:

- Definite: 3 or more criteria
- Possible: 2 criteria
- Unlikely: <2 criteria

The overall treatment of HHT is oriented towards the predominant clinical manifestation and its severity (10, 20). PAVMs can be successfully treated with embolization although this is not a permanent solution and requires continued monitoring. The recommendation for PAVM embolization is to embolize an area of 3 mm or more in diameter in order to reduce thromboembolic complications (8-17). HHT patients require antibiotic prophylaxis prior to performance of dental procedures and invasive medical procedures in order to prevent the development of brain abscesses (21).

REFERENCES

1. Sutton HG. Epistaxis as an indication of impaired nutrition, and of degeneration of the vascular system. Med Mirror 1864;1:769.
2. Babington BG. Hereditary epistaxis. Lancet. 1865;2:362-3.
3. Rendu M. Epistaxis repetees chez un sujet porteur de petits angiomes cutanes et muquex. Bull Mem Soc Med Hop Paris. 1896;13:731-34.
4. Osler W. On a family form of recurring epistaxis associated with multiple telangiectases of the skin and mucous membranes. Bull Johns Hopkins Hosp. 1901;12:333-7.
5. Weber FP. Multiple hereditary developmental angiomata (telangiectases) of the skin and mucous membranes associated with recurring haemorrhages. Lancet. 1907;ii:160-2.
6. Hanes FM. Multiple hereditary telangiectasis causing hemorrhage (hereditary hemorrhagic telangiectasia). Bull Johns Hopkins Hosp. 1909;20:63-73.
7. Chuan-Qiang Q, Shou-Gang G, Yan H, Yu-Xin C. CT Manifestations of Osler-Weber-Rendu Syndrome in Liver: Report of Three Cases. J Clin Imaging Sci. 2012;2:26.
8. Guttmacher AE, Marchuk DA, White RI. Hereditary hemorrhagic telangiectasia. N Engl J Med. 1995;333(14):918-24.
9. Westermann CJJ, Rosina AF, De Vries V, de Coteau PA. The prevalence and manifestations of hereditary hemorrhagic telangiectasia in the Afro-Caribbean population of the Netherlands Antilles: a family screening. Am J Med Genet A. 2003;116A(4):324-8.
10. Govani FS, Shovlin CL. Hereditary haemorrhagic telangiectasia: a clinical and scientific review. Eur J Hum Genet. 2009;17(7):860-71.
11. Fernández-L A, Sanz-Rodriguez F, Blanco FJ, Bernabéu C, Botella LM. Hereditary hemorrhagic telangiectasia, a vascular dysplasia affecting the TGF-beta signaling pathway. Clin Med Res. 2006;4(1):66-78.
12. Kjeldsen AD, Møller TR, Brusgaard K, Vase P, Andersen PE. Clinical symptoms according to genotype amongst patients with hereditary haemorrhagic telangiectasia. J Intern Med. 2005;258(4):349-55.
13. Sharathkumar AA, Shapiro A. Hereditary haemorrhagic telangiectasia. Haemophilia. 2008;14(6):1269-80.
14. Begbie ME, Wallace GMF, Shovlin CL. Hereditary haemorrhagic telangiectasia (Osler-Weber-Rendu syndrome): a view from the 21st century. Postgrad Med J. 2003;79(927):18-24.
15. Maldonado LV, Absceso intramedular en paciente con enfermedad de Rendu-Osler-Weber. Medicina. 2007:714-16.
16. Grand'Maison A. Hereditary hemorrhagic telangiectasia. CMAJ. 2009;180(8):833-5.
17. Tabakow P, Jarmundowicz W, Czapiga B, Czapiga E. Brain abscess as the first clinical manifestation of multiple pul-

monary arteriovenous malformations in a patient with hereditary hemorrhagic telangiectasia (Rendu-Osler-Weber disease). Folia Neuropathol. 2005;43(1):41-4.
18. Mathis S, Dupuis-Girod S, Plauchu H, Giroud M, Barroso B, Ly KH, et al. Cerebral abscesses in hereditary haemorrhagic telangiectasia: a clinical and microbiological evaluation. Clin Neurol Neurosurg. 2012;114(3):235-40.
19. Shovlin CL, Guttmacher AE, Buscarini E, Faughnan ME, Hyland RH, Westermann CJ, et al. Diagnostic criteria for hereditary hemorrhagic telangiectasia (Rendu-Osler-Weber syndrome). Am J Med Genet. 2000;91(1):66-7.
20. Faughnan ME, Palda VA, Garcia-Tsao G, Geisthoff UW, McDonald J, Proctor DD, et al. International guidelines for the diagnosis and management of hereditary haemorrhagic telangiectasia. J Med Genet. 2011;48(2):73-87.
21. Olitsky SE. Hereditary hemorrhagic telangiectasia: diagnosis and management. Am Fam Physician. 2010;82(7):785-90.