

Hystometric evaluation of nickel chronic exposure effects on large intestine of adult Wistar male rats

Evaluación histométrica de los efectos de la exposición crónica al níquel en el intestino grueso de ratas macho Wistar adultas

Maria Luiza Assis Rodrigues¹, Sirlene Souza Rodrigues Sartori², Priscila Izabel Santos Totaro³, Sérgio Luis Pinto da Matta⁴.

ARTICLE DATA

¹ Bacharela of Biological Sciences, Universidade Federal de Viçosa, Viçosa, Brasil, mlar2205@gmail.com.

² Doctor in Biologia Celular e Estrutura, Universidade Federal de Viçosa, Viçosa, Brasil, sirlene.rodrigues@ufv.br

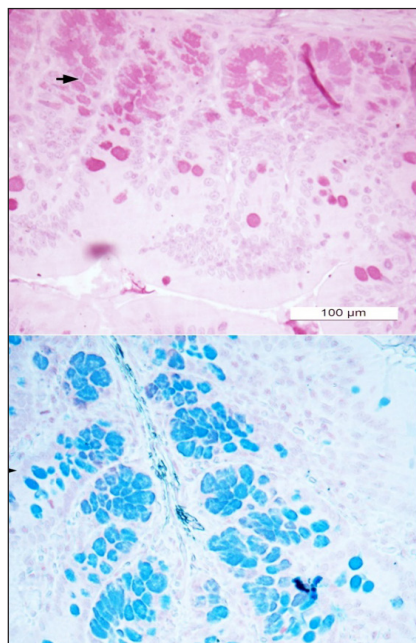
³ Doctor in Biologia Celular, Universidade Federal de Minas Gerais, Belo Horizonte, Brasil,

⁴ Doctor em Biologia Celular, Universidade Federal de Viçosa, Viçosa, Brasil, smatta@ufv.br

Cite: Rodrigues, M., Sartori, S., Totaro, P. & da Matta, S. (2019). Hystometric evaluation of nickel chronic exposure effects on large intestine of adult Wistar male rats. *Revista de Ciências Agrícolas*. 36(E): 21-30 doi: <https://doi.org/10.22267/rcia.1936E.103>

Received: June 22 2019.

Accepted: October 16 2019.



ABSTRACT

The ingestion of considerable amounts of water or food contaminated with nickel can be very toxic. The present work was conducted aiming to evaluate the effects of nickel exposures on ascending colon of adult Wistar male rats at hystometric level. We used 12 animals that were divided in a control (ingested uncontaminated water) and a nickel-contaminated (i.e., 25 mg de nickel/L of water) groups. Nickel chloride was offered in declorinated water and the experiment had a 56 days exposure period. A portion of the ascending colon was removed of the animals and subjected to hystological labelling processes using blue toluidin (for general hystometric description), Alcian Blue (AB, for acid mucins) and periodic acid-Schiff (PAS) technique (for neutral mucins). The potential differences between groups were designed by applying the Whitney test and *t* test ($p < 0.05$). The crypts were smaller for the nickel-contaminated group, even though these organism exhibited broader and higher crypts. Nickel-contaminated animals exhibited a smaller amount of calyceform cells with AB and PAS positive reactions as well as a less mucus quantities when compared with nickel-uncontaminated animals. Such reductions on the amount of calyceform cells with AB and PAS positive reactions may be related wiht the shallower crypts, which possibly reduced the synthesis and secretion of mucins, compromissing the functional aspects (e.g., lubrication and intestinal mucosa protection) of the nickel-contaminated large intestines. Interestingly, the wider and higher crypts and higher epithelium collumn on the nickel-contaminated animals may represent a relevant trade-off for the intestinal mucosa protection.

Keywords: nickel contamination, toxicology, hystology, morphology.

RESUMEN

La ingestión de cantidades considerables de agua o alimentos contaminados con níquel puede ser muy tóxica. El presente trabajo se realizó con el objetivo de evaluar los efectos de las exposiciones al níquel en el colon ascendente de ratas macho Wistar adultas a nivel histométrico. Utilizamos 12 animales que se dividieron en un control (agua ingerida no contaminada) y un grupo contaminado con níquel (es decir, 25 mg de níquel / L de agua). Se ofreció cloruro de níquel en agua desclorinada y el experimento tuvo un período de exposición de 56 días. Una parte del colon ascendente se retiró de los animales y se sometió a procesos de marcaje histológico usando toluidina azul (para descripción histométrica general), azul de Alcian (AB, para mucinas ácidas) y la técnica periódica de ácido-Schiff (PAS) (para mucinas neutras). Las diferencias potenciales entre los grupos se diseñaron mediante la aplicación de la prueba

de Whitney y la prueba t ($p < 0.05$). Las criptas eran más pequeñas para el grupo contaminado con níquel, a pesar de que estos organismos exhibían criptas más amplias y más altas. Los animales contaminados con níquel exhibieron una menor cantidad de células caliceiformes con reacciones positivas AB y PAS, así como una menor cantidad de moco en comparación con los animales no contaminados con níquel. Dichas reducciones en la cantidad de células caliceiformes con reacciones positivas AB y PAS pueden estar relacionadas con las criptas menos profundas, lo que posiblemente redujo la síntesis y secreción de mucinas, comprometiendo los aspectos funcionales (p. Ej., lubricación y protección de la mucosa intestinal) del intestino grueso contaminado con níquel. Curiosamente, las criptas más anchas y más altas y la columna de epitelio más alta en los animales contaminados con níquel pueden representar una compensación relevante para la protección de la mucosa intestinal.

Palabras clave: contaminación de níquel, toxicología, histología, morfología.

INTRODUCTION

Nickel is a heavy metal naturally found in the earth's crust at about 0.009%, existing as soluble and insoluble compounds in soils and waters (Bertini *et al.*, 2001). However, the environmental nickel concentration has increased due to the anthropogenic actions (mining and industrial activities) that are involved in the production of clocks, mobil phones, coins and cardiovascular stents (Schmidt and Goebeler, 2011).

The daily nickel requirements by human beings is estimated to be between 5 and 50 μ g (EMEA, 2008), which has leading it to be considered as 'potential essential' for animals, including humans, in 1970's (Nielsen and Ollerich, 1974). Interestingly, such categorization was based on some experiments using model animals but exclude the fact that no nickel-containing enzymes were found on such investigations. The potential reasons for this nickel need are still controversial but may be related to the use of nickel by the mammals' microbiota (Monachese *et al.*, 2012). For instance, Gerbino *et al.* (2012) demonstrated that maximum tolerated nickel (Ni^{2+}) concentrations without reductions on the biomass of *Lactobacillus kefir* CIDC3A 8348 and JCM 5818 were of 5mM and 2.5 mM, respectively, which led to the conclusion that Ni^{2+} is a essential metal in vestigial concentrations and toxic to bacteria

when in higher concentrations. Thus, when nickel is ingested in higher amounts, it becomes toxic to live organisms (Gonzalez, 2016).

The high toxicity levels of heavy metals to organisms and their easy way of enterring and accumulating along the throphic chains reinforce the relevance of investigating these metal concentrations in aquatic environments (Rocha and Azevedo, 2015). The humans daily ingest circa of 170 μ g of nickel through food and drink approximately 20 μ g of nickel. Such nickel-containing food and water ingestion have to be considered as it has been demonstrated that starving individuals absorb much more nickel on their gastrointestinal tract (Ahmad and Ashraf, 2011). The nickel absortion may vary from 12% up to 33% in starving organisms, and from 0.7 up to 6% when mixed with food (Sunderman *et al.*, 1989; Haber *et al.*, 2000). In investigations conducted with animals, it was demonstrated that nickel absorption by ingestion also varies with the nickel solubility, being higher for nickel soluble compounds, 9.8%, 11% and 34% for sulphate, chloride and nitrate ions, respectively; and lower for sulphite salts and green oxides: 0.47 and 0.01%, respectively (Haber *et al.*, 2000).

Pharmacocynetics in human beings demonstrated that nickel is absorbed through lungs, intestinal tracts and skin. In the

respiratory tract, the nickel can be removed by mucociliar transport being delivered to gastrointestinal tract, where its absorption is not high. The absorption level is influenced by metal particles' size, chemical structure, density and electric charge as well as by accumulation place in the organism (Clancy and Costa, 2012).

In the large intestine occurs the absorption of water and inorganic salts, leading to the formation of fecal bolus. To achieve that, the collunar cells present microvils in the apical surface and Na⁺/K⁺-ATPases in the basolateral membranes. The calciforme cell are in great number and the mucus contribute to the fecal bolus compactuation, facilitating the its sliding and lubricating the epithelial surface (Gartner and Hiatt, 2017; Lowe and Anderson, 2015). In addition to lubrication, which turns the fecal bolus progression an easier task, the colons' mucus barrier promote the chemical protection in the internal intestinal lumen against potential aggression against digestive enzymes, antigens and toxins (Hoebler *et al.*, 2006; Gaudier *et al.*, 2009). The mucus still present bactericidal properties, regulating the bacterial strains that are in direct contact with the epithelial surface, dificultating these organisms enter into the internal environment (Finnie *et al.*, 1995; Corfield *et al.*, 2000; Hoebler *et al.*, 2006; Gaudier *et al.*, 2009).

Thus, this research was conducted aiming to evaluate the nickel effects on the ascending colon of adult Wistar male rats at hystometric level and trying to correlate the potential alterations with the functional aspects of digestory tract.

MATERIAL & METHODS

Animals, treatment and material collection. The animals were handled and euthanized according to the Animal Research Ethical Principles established by the Colégio Brasileiro de Experimentação Animal (COBEA, i.e., Brazilian College of Animal Experimentation - Protocol 001/11). Twelve adult Wistar rats of the same age (90 days), weighing between 276 and 302g, from the Central Biottery of the Center for Biological and Health Sciences at Universidade Federal de Viçosa (UFV, Viçosa, Minas Gerais, Brasil) were used. The animals were kept in the biottery of the Health and Nutrition Department at UFV throughout the experimental period (56 days). The ambient temperature was 22 ± 1°C and the photoperiod 12:12h (light:dark). The animals were divided into two groups (of six individuals each), individually housed in cages (18 x 34 x 41cm) and fed daily (at 9:00 a.m.) with 30g of pelleted commercial food (Labcil, SOCIL, São Paulo, São Paulo, Brasil). The control group received free water and whereas the nickel-treated animals received 25mg of nickel chloride/L of tap drinking water over the experimental period. We monitored the average daily intake of 30mL of water per animal, which corresponds to a nickel consumption of 0.75mg/day. The animals were weighed every two weeks in order to evaluate the weight gain.

After the experimental period, the animals were anesthetized using 30mg/Kg of the commercial combination of ketamine and xylazine (Xylazin and Cetamin, Syntec, Santana de Parnaíba, São Paulo, Brasil) and euthanized by prolongating anesthesia. After that, the animals were weighed, and a cranial portion fragment of the ascending colon was removed of each animal. The fragments were then fixed in Karnovsky solution for 24 h and then left in 70% alcohol.

Hystometric evaluations of ascending colon region. The fixed ascending colon fragments were dehydrated in a growing ethyl series (alcohol 80, 90, 95% and absolute I) and included in historesin. Semi-serial sections of 3 μ m thickness were obtained using a rotating microtome (model RM2245, Leica, Lincolnshire, Buffalo Grove, United States). The sections were stained with toluidine blue (in 1% sodium borate) for tissue hystomorphological description and hystometric analysis, with periodic acid-Schiff (PAS) and Alcian Blue (pH 2.5) techniques for quantifications of neutral and acidic, respectively, mucin-producing cells and the stored mucus in these cells.

Observations and photographic recordings of the sections were performed under an optical microscope with an attached digital camera (model BX53, Olympus, Miami, Florida, United States) and photomicrographs were obtained using the 10x objectives for the intestinal crypt's depth and width (at midpoint) and for height apical epithelium height. Objectives of 20x were used for photomicrographs used at the quantification of other caliciform cells and PAS- and AB-positive mucus-producing cells. Five fragments of each animal were randomly selected, and photomicrographs were obtained of five fragment fields per each fragment, totaling 25 photomicrographs per animal and 150 photomicrographs per animal group (control and nickel-contaminated animals).

To obtain the hystometric data, the photomicrographs obtained were digitalized and analyzed using the Image J software (Media Cybernetics, Inc, Madison, Wisconsin, United States). From the histological images, we conducted five measurements for each parameter (depth and width of intestinal crypts and height of the apical epithelium), obtaining 125 measurements/animal/ parameter. The

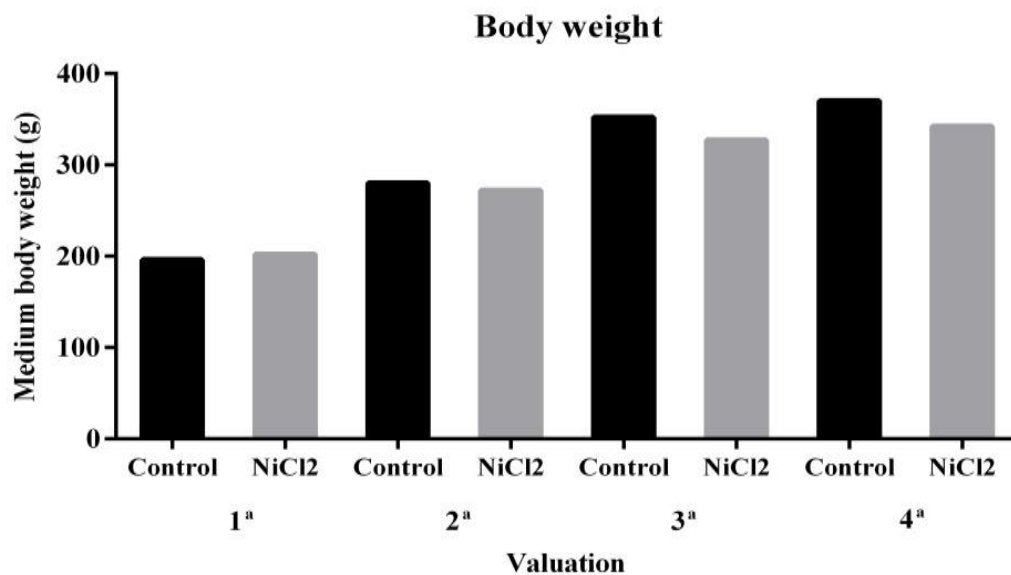
quantification of caliciform cells and PAS- and AB-positive mucus-producing cells per μ m² (photographic field area) were obtained by counting all stained cells in the field.

Statistical analyses. The normality of Kolmogorov-Smirnov and homoscedasticity of Cochran tests were conducted using the Prisma (Graphpad software, San Diego, California, United States) software. Once these assumptions were achieved, a t-test ($P < 0.05$) was conducted for comparing the values obtained for nickel-unexposed (control) and nickel-treated animals. When the normality and homoscedasticity were not achieved, it was conducted such comparison using the Mann-Whitney nonparametric test ($P < 0.05$).

RESULTS AND DISCUSSION

Some researchers and toxicologists are focusing on the risk of environmental pollution by heavy metals, which are dangerous and cause effects related to animal studies, toxic effects due to oral exposure, with the possibility of slow development (Domshlak *et al.*, 2005).

In the present study, the animals used with 25 mg/L NiCl₂ showed no significant changes ($P > 0.05$) in body weight, although there was a tendency to decrease in weight gain (Figure 1). Several studies have evaluated nickel toxicity by oral exposure at different chronic doses, and a significant reduction in body weight has been observed (Dieter *et al.*, 1988; Obone *et al.*, 1999; Cempel and Janicka, 2002; Gill *et al.*, 2002). The toxic effects by chemicals in biological systems are determined by the concentration mechanism and the exposition time (Oga *et al.*, 2008). Therefore, the dose used in this study may not have been sufficient to cause significant reduction in body weight of these animals.

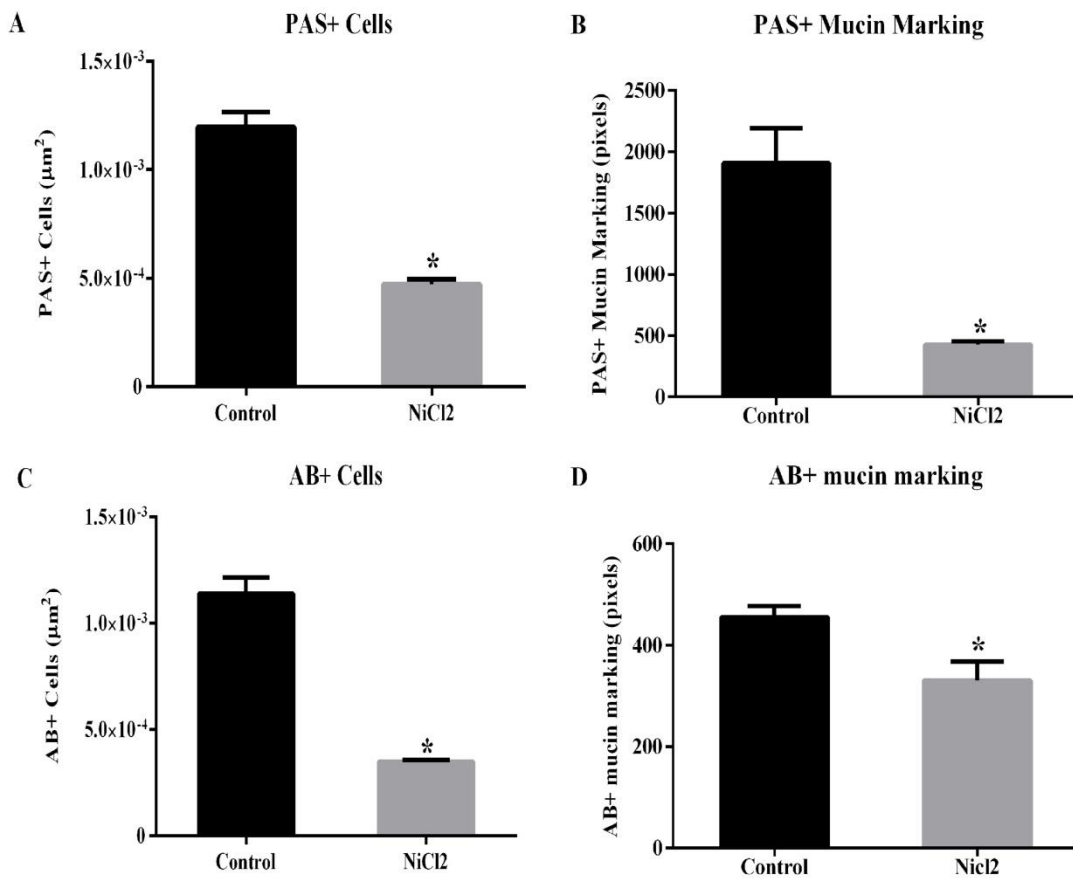


There was no statistically significant difference. Data are expressed as mean \pm standard error (SE). * $P < 0.05$ (t- test).

Figure 1. Effect of nickel chloride exposure on body weight of adult male Wistar rats. Four weight measurements were performed at two week intervals.

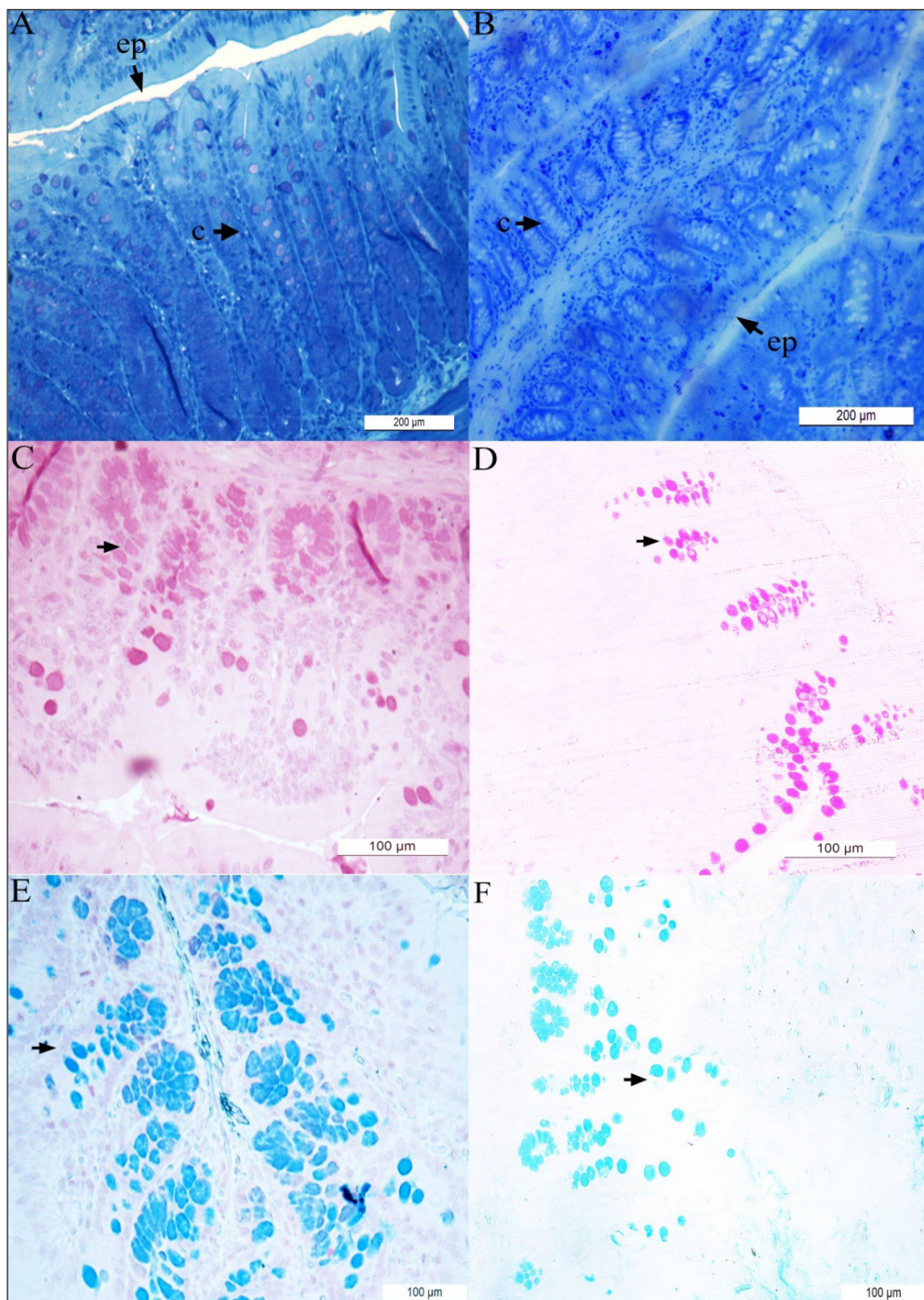
However, the other hystometric evaluated parameters showed significant differences between the animal groups (Figures 2 and Figure 3). Here, it was showed a reduction in the number of calciform cells and in the amount of PAS- (Figures 2A and B; 3C and D) and AB-positive mucus (Figure 2C and D; Figures 3E and F) in the large intestine of nickel-exposed Wistar male rats. The number of calciform cells demonstrates the potential for mucus secretion and colonic gland activity (Glotzer *et al.*, 1981). Changes in the composition and pattern of mucin secretion in the intestinal crypts have been observed in several inflammatory diseases that reach the

colon, such as bacterial colitis, nonspecific ulcerative colitis, Crohn's disease, exclusion colitis, adenomatous polyps and colorectal cancer (Filipe 1969; Finnie *et al.*, 1995; Keli *et al.*, 1997;). In nonspecific colitis, the total production of acid and neutral mucins are reduced, being absent in some cases and in regions with severe inflammatory process (Filipe, 1969). Thus, a reduction in mucin secretion is seen as a detrimental effect in the intestinal protection and lubrication as well as in mucin-mediated processes such as cell-cell and cell-substrate interactions, wounding and immune response modulations (Kim and Gum, 1995).



data are expressed as mean ± standard error (SE). * $P < 0.05$ (t- test).

Figure 2. Effects of nickel chloride exposure on the number of calciform cell with PAS- (**A**) and AB- (**C**) positive reactions (**A** and **C**, respectively) on colon of adult Wistars rats. The intensity of PAS- and AB-positive mucin marking (**B** and **D**) were also presented.



The results obtained for control (i.e., nickel-unexposed) animals are presented in panels (A), (C) and (E) while the results obtained for nickel(25mg/L)-exposed animals are presented in panels (B), (D) and (F). The epithelium (**ep**) and intestinal crypts (**c**) are shown in the material stained with toluidine blue (A – B). Material stained with periodic acid-Schiff (PAS) (C – D) and Alcian Blue (AB) (E – F) techniques are also shown. The arrowheads indicated the neutral (C – D) and acid (E – F) mucin-producing cells.

Figure 3. Hystological microphotographies of colon of Wistar rats.

The decrease in crypt depth (Figures 3A and B; Figure 4A) reflects the reduction in the number of mucus producing cells. Previous studies have shown that animals that had their fecal transit decreased, also had a decrease in the number of mucous cells, which led to significant reduction in crypt depth (Mello *et al.*, 2012). In the present investigation, it was also demonstrated an

increase in crypt width (Figures 3A and B; Figure 4B) and epithelium height (Figure 3A and B; Figure 4C) in animals exposed to nickel chloride. Such changes can be understood as a compensatory mechanism for protection of intestinal mucosa, as the mucus barrier was subjected to relevant alterations (reduction in the number of caliciform cells).

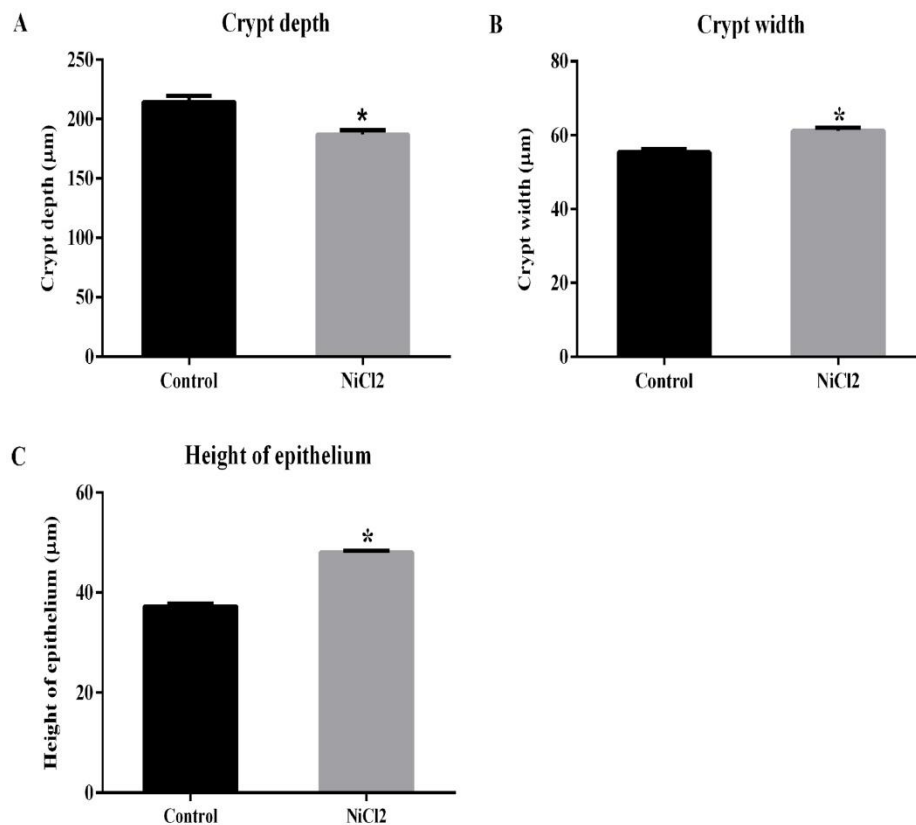


Figure 4. Effect of nickel chloride exposures on the colon of adult Wistars rats. Crypt's depth (**A**) and width (**B**). (**C**) Epithelium height. Data are expressed as mean \pm standard error (SE). * $P < 0.05$ (Mann-Whitney test).

CONCLUSIONS

The chronic exposure to nickel impacted the colong region of Wistar adult male rats. The smaller number of caliciform cells and lower PAS- and AB-positive mucus production is certainly related to reduced crypt depth in nickel-exposed animals, which may compromised the functional aspects of the large intestine (e.g., lubrication and protection of the intestinal mucosa). The larger values for crypt width and epithelium height may be a compensatory mechanism for protection of the intestinal mucosa as the mucus barrier was also altered.

Conflict of interest: The authors declare that there is no conflict of interest.

BIBLIOGRAPHIC REFERENCES

- Ahmad, M. S. & Ashraf, M. (2011). Essential roles and hazardous effects of nickel in plants. *Rev. Environmental Contamination and Toxicology*. 214: 125-167. doi: http://dx.doi.org/10.1007/978-1-4614-0668-6_6
- Bertini, I., Sigel, A. & Sigel, H. (2001). *Handbook on Metalloproteins*. 1th ed. New York: Marcel Dekker. 1182p.
- Cempel, M., Janicka, K. (2002). Distribution of nickel, zinc, and copper in rat organs after oral administration of nickel (II) chloride. *Biological Trace Element Research*. 90 (1-3): 215-226. doi: 10.1385/BTER:90:1-3:215
- Clancy, H. & Costa, M. (2012). Nickel: A pervasive carcinogen. *Future Oncology*. 8 (12): 1507-1509. doi:10.2217/fon.12.154
- Corfield, A.P., Myerscough, N., Longman, R., Sylvester, P., Arul, S. & Pignatelli, M. (2000). Mucins mucosal protection in the gastrointestinal tract: new prospects for mucins in the pathology of gastrointestinal disease. *Gut*. 47 (4): 589-594. doi: <http://dx.doi.org/10.1136/gut.47.4.589>
- Dieter, M. P., Jameson, C. W., Tucker, A. N. (1988). Evaluation of tissue disposition, myelopoietic, and immunologic responses in mice after long-term exposure to nickel sulfate in the drinking water. *Journal of Toxicology Environmental Health*. 24 (3): 356-372. doi: 10.1080/15287398809531167
- Domshlak, M. G., Elakov, A. L., Osipov, A. N. (2005). Genetic effects induced by nickel sulfate in germline and somatic cells of WR mice. *Russian Journal of Genetics*. 41(7): 728-734
- EMEA - Europe, the Middle East and Africa. (2008). Guideline on the Specification Limits for Residues of Metal Catalysts or metal Reagents, European Medicines Agency. Retrieved from https://www.ema.europa.eu/en/documents/scientific-guideline/guideline-specification-limits-residues-metal-catalysts-metal-reagents_en.pdf.
- Filipe, M. I. (1969). Value of histochemical reactions for mucosubstances in the diagnosis of certain pathological conditions of the colon and rectum. *Gut*. 10(7): 577-586. doi: <http://dx.doi.org/10.1136/gut.10.7.577>
- Finnie, I.A., Dwarakanath, A.D., Taylor, B.A. & Rhodes, J.M. (1995). Colonic mucins synthesis is increased by sodium butyrate. *Gut*. 36(1): 93-99. doi: <http://dx.doi.org/10.1136/gut.36.1.93>
- Gartner, L.P. & Hiatt, J.L. (2017). *Tratado de histologia*. 4th ed. Rio De Janeiro: Elsevier. 325p.
- Gaudier, E., Rival, M., Buisine, M.P., Robineau, I. & Hoebler, C. (2009). Butyrate enemas upregulate Muc genes expression but decrease adherent mucus thickness in mice colon. *Physiological research*. 58 (1): 111-119.
- Gerbino, E., Mobili, P., Tymczyszyn, E., Frausto-Reyes, C., Araujo-Andrade, C. & Gómez-Zavaglia, A. (2012). Use of Raman spectroscopy and chemometrics for the quantification of metal ions attached to *Lactobacillus kefir*. *Journal of applied microbiology*. 112 (2): 363-371. doi: 10.1111/j.1365-2672.2011.05210

- Gill, S., Kavanagh, M., Cherry, W., Bourque, C., Caldwell, D., Wang, G., Bondy, G. (2002). A range-finding 90-day oral (gavage) toxicity study in Fischer 344 rats with nickel sulfate hexahydrate. *Food. Chem. Toxicol.* 111: 341-355. doi: 10.1016/j.fct.2017.10.055
- Glotzer, D.J., Glick, M.E. & Goldman, H. (1981). Proctitis and colitis following diversion of fecal stream. *Gastroenterology.* 80 (3): 438-441.
- Gonzalez, K.R. (2016). Toxicologia do Níquel. *Revista intertox de toxicologia risco ambiental e sociedade.* 9 (2): 30-54.
- Haber, L.T., Erdreicht, L., Diamond, G.L., Maier, A.M., Ratney, R., Zhao, Q. & Dourson, M.L. (2000). Hazard identification and dose response of inhaled nickel soluble salts. *Regul Toxicol Pharmacol.* 31 (2): 210-30. doi:10.1006/rtph.2000.1377.
- Hoebler, C., Gaudier, E., De Coppet, P., Rival, M. & Cherbut, C. (2006). MUC genes are differentially expressed during onset, maintenance of inflammation in dextran sodium sulfate-treated mice. *Dig Dis Sci.* 51 (2): 381-389. doi: http://dx.doi.org/10.1007/s10620-006-3142-y
- Keli, E., Bouchoucha, M., Devroede, G., Carnot, F., Ohrant, T., Cugnenc, P.H. (1997) Diversion-related experimental colitis in rats. *Dis Colon Rectum.* 40 (2): 222-228.
- Kim, Y.S. & Gum, J.R. (1995). Diversity of mucin genes, structure, function, and expression. *Gastroenterology.* 109 (3): 999-1013.
- Lowe, J.S. & Anderson, P.G. (2015). *Stevens & Lowe's Human Histology.* 4th ed. Philadelphia: Elsevier Mosby. 429p.
- Mello, R.O., Fonte, F.P., Silva, C.M.G., Pereira, J.A., Margarido, N.F. & Martinez, C.A.R. (2012). Avaliação do número de células caliciformes nas criptas da mucosa colônica com e sem trânsito intestinal. *Revista do Colégio Brasileiro de Cirurgiões.* 39 (2): 139-45. doi: 10.1590/S0100-69912012000200010
- Monachese, M., Burton, J. P. & Reid, G. (2012). Bioremediation and tolerance of humans to heavy metals through microbial processes: a potential role for probiotics. *Appl. Environ. Microbiol.* 78 (18): 6397-6404. doi: http://dx.doi.org/10.1128/AEM.01665-12
- Nielsen, F.H. & Ollerich, D.A. (1974). Proceedings: Nickel: a new essential trace element. *Federation proceedings.* 33 (6): 1767-1772.
- Obone, E., Chakrabarty, S. K., Bai, C., Malick, M. A., Lamantagne, L., Subramanian, K. S. (1999). Toxicity and bioaccumulation of nickel sulphate in Sprague-Dawley rats following 13 weeks of subchronic exposure. *Journal of Toxicology and Environmental Health.* 57 (6): 379-401
- Oga, S., Camargo, M. M. A., Batistuzzo, J. A. O. (2008). *Fundamentos de Toxicologia.* 4 th ed. São Paulo: Atheneu. 677p.
- Rocha, C.H.B. & Azevedo, L.P. (2015). Assessing the presence of heavy metals in surface Waters of the São Mateus Brook Basin, Juiz de Fora (MG), Brazil. *Revista Espinhaço.* 4 (2): 33-44.
- Schmidt, M. & Goebeler, M. (2011). Nickel allergies: paying the toll for innate immunity. *J. Mol. Med. (Berl).* 89 (10): 961-970. doi: 10.1007/s00109-011-0780
- Sunderman, F.W., Hopfer, S.M., Sweeney, K.R., Marcus, A.H., Most, B.M. & Creason, J. (1989). Nickel absorption and kinetics in human volunteers. *Proc Soc Exp Biol Med.* 191(1): 5-11. doi: 10.3181/00379727-191-42881