

Original Investigation

Real-world nailfold videocapillaroscopy in a referral centre in north-western Colombia: A real-life cohort

Diana Cristina Varela^a, Johann Gutiérrez Bolaños^b, Libia María Rodríguez Padilla^c, Miguel Antonio Mesa Navas^{c,d,e}, Carlos Jaime Velásquez-Franco^{c,d,e,*}

^a Department of Rheumatology, School of Health Sciences, Universidad Pontificia Bolivariana, Medellín, Colombia

^b Department of Internal Medicine, Clínica Universitaria Bolivariana, Medellín, Colombia

^c UNIR Research Group, School of Health Sciences, Universidad Pontificia Bolivariana, Medellín, Colombia

^d Department of Rheumatology, School of Health Sciences, , Clínica Universitaria Bolivariana, Medellín, Colombia

^e EULAR Study Group on Microcirculation in Rheumatic Diseases

ARTICLE INFO

Article history:

Received 28 January 2021

Accepted 20 April 2021

Available online 31 March 2023

Keywords:

Microscopic angiopathy

Raynaud disease

Scleroderma

Systemic

ABSTRACT

Introduction: Nailfold videocapillaroscopy is a non-invasive tool for the assessment of peripheral microcirculation, the main indication is the study of Raynaud's phenomenon, poorly standardized outside of this context. There is no clear information in real-life about the reasons for referral, the presence of clinical findings of autoimmune diseases, the frequency of patterns of autoantibodies, and specific capillaroscopic findings.

Objective: The purpose of this survey is to describe the sociodemographic, clinical, paraclinical, and angiopathy findings of a cohort of subjects referred to a capillaroscopy service in North-western Colombia.

Methods: A retrospective study was conducted, from 2015 to 2018. Categorical variables were expressed in frequency and percentage and quantitative variables in mean and standard deviation or median with interquartile range, depending on the distribution of the data.

Results: A total of 318 capillaroscopies were performed for the first time. The main referral reason was Raynaud's phenomenon (n = 134; 42.1%). The most frequent baseline capillaroscopic pattern found was normal (n = 123; 38.7%). Of the 12 capillaroscopies that presented a non-specific pattern at a 6-month follow-up, only one (8.3%) progressed to a scleroderma pattern. In the subjects with systemic sclerosis, the most frequent clinical finding was sclerodactyly (n = 34; 37.8%), and 42/44 individuals (95.4%) had positive antinuclear antibodies; the most frequent pattern was centromere (n = 27; 64.3%)

Conclusions: In a real-world setting, the main referral reason for capillaroscopy was Raynaud's phenomenon; more than a third of the subjects had normal capillaroscopic findings. Sclerodactyly was the most frequent clinical finding in patients with scleroderma capillaroscopic pattern.

© 2021 Asociación Colombiana de Reumatología. Published by Elsevier España, S.L.U. All rights reserved.

Videocapilaroscopia de la vida real en un centro de referencia del noroccidente colombiano: cohorte de la vida real

R E S U M E N

Palabras clave:

Angioscopia microscópica
Enfermedad de Raynaud
Esclerodermia sistémica

Introducción: La videocapilaroscopia del lecho ungular es una herramienta no invasiva para la evaluación de la microcirculación periférica; la indicación principal es el estudio del fenómeno del Raynaud. Luego de una revisión de la literatura, no hay información clara sobre los motivos de remisión, presencia de hallazgos clínicos de enfermedades autoinmunes, frecuencia de patrones de autoanticuerpos y hallazgos capilaroscópicos específicos.

Objetivo: Describir los hallazgos sociodemográficos, clínicos, paraclínicos y capilaroscópicos de sujetos remitidos a un servicio de capilaroscopia en el noroccidente colombiano.

Métodos: Estudio retrospectivo, de 2015 a 2018. Las variables categóricas se expresaron en frecuencias absolutas y porcentajes y las variables cuantitativas en media y desviación estándar o mediana con rango intercuartílico, dependiendo de la distribución de los datos.

Resultados: Se realizaron 318 capilaroscopias por primera vez. El principal motivo de remisión fue el fenómeno de Raynaud (n = 134; 42.1%). El patrón capilaroscópico basal más frecuente fue el normal (n = 123; 38.7%). De las 12 capilaroscopias que presentaron un patrón no específico, en un seguimiento de seis meses, sólo una (8.3%) progresó a un patrón de esclerodermia. En los sujetos con esclerosis sistémica, el hallazgo clínico más frecuente fue la esclerodactilia (n = 34; 37.8%), y 42/44 individuos (95.4%) tenían anticuerpos antinucleares positivos; el patrón más frecuente fue el centromérico (n = 27; 64.3%).

Conclusiones: La razón principal de remisión para realizar una capilaroscopia fue el fenómeno de Raynaud; más de un tercio de los sujetos tenían hallazgos capilaroscópicos normales. La esclerodactilia fue el hallazgo clínico más frecuente en pacientes con patrón capilaroscópico de esclerodermia.

© 2021 Asociación Colombiana de Reumatología. Publicado por Elsevier España, S.L.U. Todos los derechos reservados.

Introduction

Capillaroscopy is a non-invasive and reproducible imaging method that allows to evaluate structural changes in the peripheral microcirculation.¹ This procedure has different purposes, such as: evaluation of patients with Raynaud's phenomenon (RF), monitorization of the transition from primary to secondary RF, early diagnosis of systemic sclerosis (SSc) and the differential diagnosis of acrovascular syndromes.²⁻⁴

Despite being a procedure frequently used in clinical practice, there is no uniform consensus about its indications; Some authors have suggested the following:⁵

- Evaluation of the RF and differentiation between the primary and secondary RF, being able to contribute to the early diagnosis of a systemic autoimmune disease.
- Diagnosis of SSc.
- Differential diagnosis of undifferentiated connective tissue disease that presents RF as a clinical manifestation.
- Follow-up of non-specific findings: it has been found that a connective tissue disease can be found in up to 20% of these subjects if capillaroscopic evaluation is performed every six months for two years.

In addition to capillaroscopic evaluation, certain clinical findings help to confirm or rule out the presence of SSc: sclerodactyly, diffuse edema of the fingers, sclerosis cutis proximal to the metacarpophalangeal joints, limited mouth

opening, platysma sign, and presence of "pitting scars" or digital ulcers, among other findings.⁶ Other diagnostic aids, such as autoantibodies, allow to correlate and increase the diagnostic probability and provide relevant prognostic information.⁷

As for the capillaroscopic follow-up, changes over time are described for SSc (patterns: early, active, and late); the approximate time of progression from an early to an active stage and from an early to a late stage is 28 ± 20 months vs. 36 ± 29 months, respectively; likewise, clinical symptoms progress, along with capillaroscopic changes, by 60%.^{8,9}

After an extensive and pragmatic literature review, little information is found in daily clinical practice on the reasons for referral to perform a capillaroscopy, the presence of clinical findings of autoimmune diseases that can be detected during the performance of this procedure, as well as the frequency of autoantibody patterns and capillaroscopic findings specific of SSc.

The purpose of this study was to describe the sociodemographic, clinical and laboratory findings of patients treated in a capillaroscopy service in North-western Colombia.

Materials and methods

Patients

A retrospective study was conducted in patients who were referred to a capillaroscopy referral center in North-western Colombia between January 2015 and December 2018; all

patients over 18 years of age who underwent this procedure were included, without any exclusion criteria.

Clinical variables

The following data from the patients were collected: sex, age, reason for performing capillaroscopy, clinical manifestations of SSc and antinuclear antibodies at the time of the examination (dilution and pattern); comorbidities were not included. These data were compiled in a form.

As part of the evaluation prior to capillaroscopy, two rheumatologists who meet the definition of experts from the Capillaroscopy Study Group of the Pan American League of Associations of Rheumatology (PANLAR)¹⁰ reached consensus on the variables of interest for the study; subsequently, they carried out a baseline clinical evaluation of the patients, actively searching for clinical signs of SSc which included: RF, defined according the flowchart of the international consensus of 2014 as: sclerodactyly, diffuse edema of the hands, digital ulcers or “rat bite” lesions (“pitting scars”), telangiectasia, microstomia and platysma sign.¹¹ Gottron’s sign and Gottron papules were also actively searched, looking for dermatomyositis.

Laboratory variables

The ambulatory report of antinuclear antibodies in any titer and pattern performed with the technique of indirect immunofluorescence was included.¹² These antibodies were carried out in different centers.

Capillaroscopic variables

The videocapillaroscope (Optilia Instruments AB, Sollentuna, Sweden), with a 200× magnification was used, operated by two expert rheumatologists (the Kappa of correlation between rheumatologists is 0.84, 95% CI: 0-66-1),¹³ once the compliance by the patients of the previous requirements for the performance of this procedure in terms of manipulation of the cuticle, coffee intake and hand washing, among others, was verified. After having applied almond oil to all the fingers of the hand, following the recommendations,¹⁴ four photos of each finger were taken in an angle of 90°.

The capillaroscopic variables included were determined according to the videocapillaroscopy semiquantitative scale defined by Cutolo et al.,¹⁵ which includes, among other characteristics: visibility, pericapillary edema, subcapillary venous plexus, number of capillaries per millimeter, largest diameter of the capillary evaluated, presence of comb-shaped capillaries, tortuous capillaries, crossing capillaries, dilated capillaries larger than 30 μm, megacapillaries larger than 50 μm, microhemorrhages, avascular areas, neovascularization and capillary disorganization; according to this scale, the patients were classified based on the capillaroscopic patterns defined by Cutolo et al.,¹⁵ into normal, non-specific, similar to SSc and SSc (active, early and late) patterns.

Based on the clinical and Capillaroscopic criteria, the 2013 classificatory criteria for SSc were applied.⁶ In addition, the records of capillaroscopies performed six months later in the subjects who presented a non-specific pattern were included,

in order to determine if there was a change in the capillaroscopic pattern found. It was not possible to include clinical information in the follow-up capillaroscopies, which were performed by the same two experts. All capillaroscopies performed between the years 2015 and 2018 were included in the analysis, regardless of the clinical diagnoses and pathological antecedents.

Statistical analysis

The categorical variables were expressed as absolute frequencies and percentages, while the quantitative variables were presented as mean and standard deviation, or as median with interquartile range (IQR), depending on the data distribution. The statistical analysis was performed using the Statistical Package for Social Sciences (SPSS® v.25, SPSS Inc., Chicago, Illinois, USA), licensed for the institution where the study was conducted.

Ethical aspects

The study was considered without risk for patients, according to current national regulations, due to its retrospective design, and was approved by the health research ethics committee of the participating institution, through act number 16 of October 31, 2018.

Results

There was a total of 392 capillaroscopies; 81% (n = 318) of the patients only required one capillaroscopy, while 18.9% had follow-up: 12% (n = 47) required two capillaroscopies, 6% (n = 21) three capillaroscopies, and 1% (n = 5) four capillaroscopies.

318 capillaroscopies were performed for the first time, 94.3% (n = 300) in women; the median age was 46.4 years (IQR: 32.8–58.9). The main characteristics of the study population are summarized in [Table 1](#).

It was found that the normal (n = 123; 38.7%) and the non-specific (n = 81; 25.5%) patterns were the most common ([Fig. 1](#)). The main reason for referral for capillaroscopy was RF.

Of the individuals referred for capillaroscopy for the first time, 160 (50.3%) had ANA, and 81.9% of them were positive. The most frequent pattern was the centromere, 59/123 (47.9%); the other patterns are schematized in [Fig. 2](#).

Sclerodactyly (n = 81; 47.9%) and “pitting scars” (n = 12; 71%) were the most frequent semiological findings. The other clinical manifestations are summarized in [Table 2](#).

Capillaroscopic follow-up was performed in 47 patients, in a period of six months; the changes in the capillaroscopic patterns are summarized in [Table 3](#).

First capillaroscopy

In 51% (24/47) of the cases there were not changes in the second capillaroscopy, 12 capillaroscopies had a non-specific pattern, only one (8.3%) progressed to a SSc pattern, and five of these were reclassified as normal pattern.

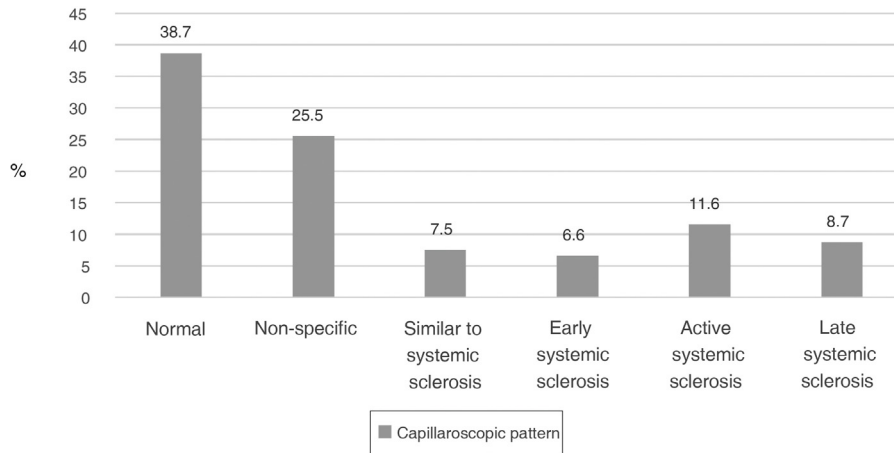


Fig. 1 – Percentage distribution of capillaroscopic patterns in a referral center in northwestern Colombia.

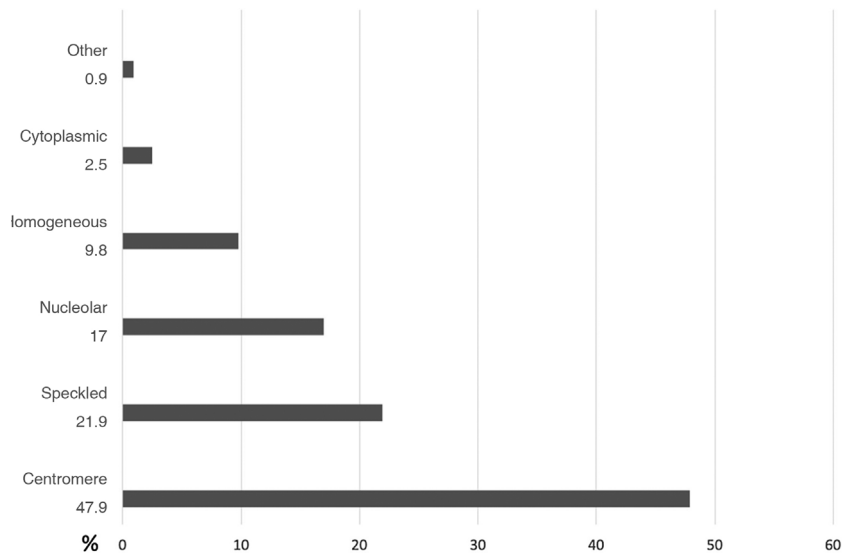


Fig. 2 – Percentage distribution of antinuclear antibodies in a referral center of capillaroscopy in northwestern Colombia.

The final diagnosis of SSc, given the clinical and capillaroscopic findings and the ANA pattern, affected 90/318 (28.3%) of the patients.

Discussion

In the present study, as far as is known, the characteristics of videocapillaroscopy in daily clinical practice, performed in a referral center, are described for the first time, and it is reported that a significant number of referred patients had a normal capillaroscopy and were referred for the study of the RF.

RF is a relatively frequent finding in the general population, with a prevalence of 3% in men and 4% in women¹⁶; in primary RF there are no changes in capillaroscopy, which occurs in 60% of the patients¹⁷; in secondary RF, the systemic autoimmune disease most frequently found is SSc. In previous

studies, videocapillaroscopy has shown good performance in assessing the progression of the SSc, with a sensitivity of 94% and a specificity of 92%¹⁷; however, the prevalence of a normal or indeterminate capillaroscopy pattern in patients with SSc can vary between 4 and 20%¹⁸; these subjects could correspond to a subgroup of this disease that is characterized by having less skin involvement, less telangiectasias and less lung involvement.

In the present study, 134 patients were referred due to RF, 63 (47%) of them had a normal capillaroscopy. It is presumed that these subjects had primary RF, therefore, 53% of these subjects had secondary RF; of them, 36.6% were explained by SSc. These findings are in agreement with what has been published in the literature.

On the other hand, secondary RF is accompanied by the presence of autoantibodies and significant tissue damage, manifested as digital ulcers or necrosis, in addition to other cutaneous manifestations such as sclerosis cutis, telangiect-

Table 1 – General characteristics in a referral center of capillaroscopy in North-western Colombia (n = 318).

Characteristics	n (%)
Sex (female)	300 (94.3)
Age (years), median (IQR)	46.4 (32.8–58.9)
Reason for referral to the capillaroscopic clinic	
Raynaud's phenomenon	134 (42.1)
Evaluation of the SSc	79 (24.8)
Connective tissue diseases other than SSc	105 (33.1)
ANA positivity n/N	131/160 (81.9)
>1:160	107/131 (81.7)
Centromere pattern	59/123 (47.9)
Speckled pattern	27/123 (21.9)
Nucleolar pattern	21/123 (17.0)
Capillaroscopic pattern (n = 318)	
Normal pattern	123 (38.7)
Non-specific pattern	81 (25.5)
Pattern similar to SSc	24 (7.5)
SSc	90 (28.3)
Early pattern	21/90 (23.3)
Active pattern	38/90 (42.2)
Late pattern	31/90 (34.4)

ANA: antinuclear antibodies; SSc: systemic sclerosis; IQR: interquartile range.

Table 2 – Distribution of the semiological signs of systemic autoimmune disease in a referral center of capillaroscopy in North-western Colombia.

Semiological sign	n (%)
Sclerodactyly	81 (47.9)
Barnett's sign	21 (12.4)
Puffy fingers	20 (11.8)
Telangiectasia	19 (11.2)
Pitting scars	12 (7.1)
Gottron's sign	10 (5.9)
Microstomia	6 (3.5)

tasias and gastrointestinal symptoms, findings that have been called "red flags".¹⁹ In the present study, the ANA pattern most associated with the capillaroscopic pattern of SSc was the centromere (47.9%); This finding is similar to that reported in other studies, in which it has been observed a prevalence of anticentromere antibodies of around 45%.^{20,21} The presence

of these antibodies, together with abnormal findings in the capillaroscopy, has an hazard ratio (HR) of 9.34 (5.85–14.9) as predictive variables of SSc.²²

The presence of semiological signs of SSc was frequently observed in this cohort; the most common in the subjects with a capillaroscopic pattern of this entity were: sclerodactyly, digital ulcers, puffy fingers and microstomia. In a Spanish cohort of 327 patients, the presence of sclerodactyly and puffy fingers constituted the highest specificity for SSc,⁶ which is consistent with the findings of this cohort.

Given that currently there is no clear consensus in the literature about how often to follow-up by videocapillaroscopy, previous studies have shown changes from primary to secondary RF of up to 20% in a 10-year follow-up, and the annual incidence of transition was 1%.²³ More than 90% of the patients with SSc and 85% of those with mixed connective tissue disease (MCTD) present RF as an early symptom²⁴; the follow-up time to find capillaroscopic changes ranges between 29 and 58 months.²⁴ The time suggested to perform follow-up capillaroscopies has been around six months, mainly in individuals who present antinuclear antibodies with titers higher than 1:160 and centromere pattern. An important finding of the present study was observed in patients with a capillaroscopy pattern with non-specific findings, because in the follow-up capillaroscopies it could be reclassified as a normal pattern in 83%, a finding that was not reported in other capillaroscopy referral centers; this may suggest the importance of the capillaroscopic follow-up in this group of patients, where there can be findings specific for SSc, or a return to normality, as occurred in this cohort.

As far as we know and we want to highlight as a strength of this study, it is the first description of the daily practice, of the clinical, paraclinical and capillaroscopic characteristics of a national referral center on this topic. Several limitations are also recognized, such as the inaccuracy of the information on the reason for referral, the scant information on comorbidities associated with microvascular changes (such as arterial hypertension or diabetes mellitus), the reduced number of capillaroscopies that had been followed-up and the absence of clinical changes of the patients during the evolution, the limited access to the medical records of their treating physician (only the reason for referral was known) and the lack of measurement of ANAs with their pattern and titer in all patients.

Table 3 – Correlation between the first and second capillaroscopies in a referral center in North-western Colombia.

	Normal	Non-specific	Similar to SSc	Early SSc	Active SSc	Late SSc	Total
Normal	11	9	0	0	0	0	20
Non-specific	5	6	0	1	0	0	12
Similar to SSc	0	1	0	0	0	0	1
Early SSc	1	1	0	0	2	0	4
Active SSc	1	1	0	0	3	0	5
Late SSc	0	0	0	0	1	4	5
Total	18	18	0	1	6	4	47

SSc: systemic sclerosis.

Conclusions

Videocapillaroscopy of the nailfold is a useful tool in the study of RF; the latter was the main reason for referral to a reference center. In the majority of cases, it was found a normal capillaroscopic pattern, in addition, almost in one third of the subjects it was possible to establish a diagnosis of SSc, with the combination of clinical, serological and capillaroscopic findings, while in a subgroup of subjects with a non-specific capillaroscopic pattern, at six months there was a change towards a normal pattern, which suggests the importance of follow-up with this procedure in light of these findings.

Funding

This research has not received specific support from public sector agencies, the commercial sector, or non-profit entities.

Conflict of interest

The authors declare that they have no conflict of interest for the preparation of this article.

REFERENCES

- Chojnowski MM, Felis-Giemza A, Olesińska M. Capillaroscopy a role in modern rheumatology. *Reumatologia*. 2016;54:67-72, <http://dx.doi.org/10.5114/reum.2016.6021>.
- Cutolo M, Pizzorni C, Sulli A. Capillaroscopy. *Best Pract Res Clin Rheumatol*. 2005;19:437-52, <http://dx.doi.org/10.1016/j.berh.2005.01.001>.
- Wu P, Huang MN, Kuo YM, Hsieh SC, Yu CL. Clinical applicability of quantitative nailfold capillaroscopy in differential diagnosis of connective tissue diseases with Raynaud's phenomenon. *J Formos Med Assoc*. 2013;112:482-8, <http://dx.doi.org/10.1016/j.jfma.2012.02.029>.
- Burmester GR, Bijlsma JWJ, Cutolo M, McInnes IB. Managing rheumatic and musculoskeletal diseases - past, present and future. *Nat Rev Rheumatol*. 2017;13:443-8, <http://dx.doi.org/10.1038/nrrheum.2017.95>.
- Mesa M, Velásquez-Franco CJ. *Capilaroscopia*. In: *La uña: de lo superficial a lo profundo*. Bogotá: Health Books Editorial; 2019.
- Melchor S, Joven BE, Andreu JL, Loza E, Garcia de Yébenes MJ, Carmona L, et al. Validation of the 2013 American College of Rheumatology/European League Against Rheumatism classification criteria for systemic sclerosis in patients from a capillaroscopy clinic. *Semin Arthritis Rheum*. 2016;46:350-5, <http://dx.doi.org/10.1016/j.semarthrit.2016.05.007>.
- Nagy Z, Cziráj L. Nailfold digital capillaroscopy in 447 patients with connective tissue disease and Raynaud's disease. *J Eur Acad Dermatol Venereol*. 2004;18:62-8, <http://dx.doi.org/10.1111/j.1468-3083.2004.00853.x>.
- Sulli A, Ruaro B, Smith V, Pizzorni C, Zampogna G, Gallo M, et al. Progression of nailfold microvascular damage and antinuclear antibody pattern in systemic sclerosis. *J Rheumatol*. 2013;40:634-9, <http://dx.doi.org/10.3899/jrheum.121089>.
- Gallucci F, Russo R, Buono R, Acampora R, Madrid E, Uomo G. Indications and results of videocapillaroscopy in clinical practice. *Adv Med Sci*. 2008;53:149-57, <http://dx.doi.org/10.2478/v10039-008-0038-4>.
- Bertolazzi C, Vargas Guerrero A, Rodríguez-Reyna TS, Sandoval H, Álvarez-Hernández E, Audisio MJ, et al. Pan-American League of Associations for Rheumatology (PANLAR) capillaroscopy study group consensus for the format and content of the report in capillaroscopy in rheumatology. *Clin Rheumatol*. 2019;38:2327-37, <http://dx.doi.org/10.1007/s10067-019-04610-5>.
- Maverakis E, Patel F, Kronenberg DG, Chung L, Fiorentino D, Allanore Y, et al. International consensus criteria for the diagnosis of Raynaud's phenomenon. *J Autoimmun*. 2014;48-49:60-5, <http://dx.doi.org/10.1016/j.jaut.2014.01.020>.
- Lee AY, Ang EB. A clinical overview of autoantibodies in general practice rheumatology. *Br J Gen Pract*. 2014;64:e599-601, <http://dx.doi.org/10.3399/bjgp14X681601>.
- Facio-Lince García A, Velásquez-Franco CJ, Zapata-Castellanos AL, Rodríguez-Padilla LM, Mesa-Navas MA. Características de la videocapilaroscopia del lecho ungular y de los anticuerpos antinucleares en una cohorte de pacientes con enfermedad autoinmune sistémica con fenómeno de Raynaud. *Rev Colomb Reumatol*. 2018;25:169-76, <http://dx.doi.org/10.1016/j.rcreu.2018.06.003>.
- Smith V, Herrick AL, Ingegnoli F, Damjanov N, De Angelis R, Denton CP, et al. Standardization of nailfold capillaroscopy for the assessment of patients with Raynaud's phenomenon and systemic sclerosis. *Autoimmun Rev*. 2020;19:102458, <http://dx.doi.org/10.1016/j.autrev.2020.102458>.
- Cutolo M, Pizzorni C, Tuccio M, Burroni A, Craviotto C, Basso M, et al. Nailfold video capillaroscopic patterns and serum autoantibodies in systemic sclerosis. *Rheumatology (Oxford)*. 2004;43:719-26, <http://dx.doi.org/10.1093/rheumatology/keh156>.
- Riera G, Vilardell M, Vaqué J, Fonollosa V, Bermejo B. Prevalence of Raynaud's phenomenon in a healthy Spanish population. *J Rheumatol*. 1993;20:66-9.
- Knobel H, Vilardell M, Marquet R, Ordiet J. *La capilaroscopia del lecho ungular en el fenómeno de Raynaud y en la esclerodermia*. *Med Clin (Barc)*. 1987;89:533-6.
- Fichel F, Baudot N, Gaitz JP, Trad S, Barbe C, Francés C, et al. Systemic sclerosis with normal or non-specific nailfold capillaroscopy. *Dermatology*. 2014;228:360-7, <http://dx.doi.org/10.1159/000360159>.
- Hughes M, Allanore Y, Chung L, Pauling JD, Denton CP, Matucci-Cerinic M. Raynaud phenomenon and digital ulcers in systemic sclerosis. *Nat Rev Rheumatol*. 2020;16:208-21, <http://dx.doi.org/10.1038/s41584-020-0386-4>.
- Avouac J, Fransen J, Walker UA, Riccieri V, Smith V, Mulleret C, et al. Preliminary criteria for the very early diagnosis of systemic sclerosis: results of a Delphi consensus study from EULAR Scleroderma Trials and Research Group. *Ann Rheum Dis*. 2011;70:476-81, <http://dx.doi.org/10.1136/ard.2010.136929>.
- Minier T, Guiducci S, Bellando-Randone S, Bruni C, Lepri G, Cziráj L, et al. Preliminary analysis of the Very Early Diagnosis of Systemic Sclerosis (VEDOSS) EUSTAR multicenter study: evidence for puffy fingers as a pivotal sign for suspicion of systemic sclerosis. *Ann Rheum Dis*. 2013;73:2087-93, <http://dx.doi.org/10.1136/annrheumdis-2013-203716>.
- Koenig M, Joyal F, Fritzler MJ, Roussin A, Abrahamowicz M, Boire G, et al. Autoantibodies and microvascular damage are independent predictive factors for the progression of Raynaud's phenomenon to systemic sclerosis: a twenty-year prospective study of 586 patients, with validation of proposed

-
- criteria for early systemic sclerosis. *Arthritis Rheum.* 2008;58:3902-12, <http://dx.doi.org/10.1002/art.24038>.
23. Hirschl M, Hirschl K, Lenz M, Katzenschlager R, Hutter HP, Kundi M. Transition from primary Raynaud's phenomenon to secondary Raynaud's phenomenon identified by diagnosis of an associated disease: results of ten years of prospective surveillance. *Arthritis Rheum.* 2006;54:1974-81, <http://dx.doi.org/10.1002/art.21912>.
24. Cutolo M, Sulli A, Secchi ME, Olivieri M, Pizzorni C. The contribution of capillaroscopy to the differential diagnosis of connective autoimmune diseases. *Best Pract Res Clin Rheumatol.* 2007;21:1093-108, <http://dx.doi.org/10.1016/j.berh.2007.10.001>.