

Genes involved in amelogenesis imperfecta. Part II*

Genes involucrados en la amelogénesis imperfecta. Parte II*

VÍCTOR SIMANCAS-ESCORCIA¹, ALFREDO NATERA², MARÍA GABRIELA ACOSTA DE CAMARGO³

* See Part I in *Revista Facultad de Odontología Universidad de Antioquia*, 2018; 30(1): 105-120. DOI: <http://dx.doi.org/10.17533/udea.rfo.v30n1a10>

¹ DDS. MSc in Cell Biology, Physiology and Pathology. PhD candidate in Physiology and Pathology, Université Paris-Diderot, France. Grupo Interdisciplinario de Investigaciones y Tratamientos Odontológicos Universidad de Cartagena, Colombia (GITOUC).

² DDS. Professor in the Department of Operative Dentistry, Universidad Central de Venezuela. Head of Centro Venezolano de Investigación Clínica para el Tratamiento de la Fluorosis Dental y Defectos del Esmalte (CVIC FLUOROSIS).

³ DDS. Specialist in Pediatric Dentistry, Universidad Santa María. PhD in Dentistry, Universidad Central de Venezuela. Professor in the Department of Dentistry of the Child and Adolescent, Universidad de Carabobo.

ABSTRACT

Amelogenesis imperfecta (AI) is a condition of genetic origin that alters the structure of tooth enamel. AI may exist in isolation or associated with other systemic conditions as part of a syndromic AI. Our goal is to describe in detail the genes involved in syndromic AI, the proteins encoded by these genes, and their functions according to current scientific evidence. An electronic literature search was carried out from the year 2000 to December 2017, pre-selecting 1,573 articles, 40 of which were analyzed and discussed. The results indicate that mutations in 12 genes are responsible for syndromic AI: DLX3, COL17A1, LAMA3, LAMB3, FAM20A, TP63, CNNM4, ROGDI, LTBP3, FAM20C, CLDN16, CLDN19. These genes participate in the coding of proteins involved in phosphorylation, ion exchange, and production and degradation of the constituent elements of the mineral and organic phase of tooth enamel. The scientific evidence confirms that AI can be part of the syndrome and requires special attention from the medical-dental community.

Keywords:

amelogenesis imperfecta, tooth enamel, tooth enamel proteins, dental aesthetics, genes, syndrome

RESUMEN

La amelogénesis imperfecta (AI) es una condición de origen genético que altera la estructura del esmalte dental. La AI puede existir de manera aislada o asociada a otras afecciones sistémicas en el contexto de una AI sindrómica. El objetivo es describir de manera detallada los genes involucrados en las AI sindrómicas, las proteínas codificadas por estos genes y sus funciones de acuerdo a la evidencia científica actual. Se realizó una búsqueda electrónica de literatura desde el año 2000 hasta diciembre de 2017, después de lo cual se preseleccionaron 1.573 artículos, de los cuales 40 fueron analizados y discutidos. Los resultados indican que mutaciones en 12 genes son responsables de una AI sindrómica: DLX3, COL17A1, LAMA3, LAMB3, FAM20A, TP63, CNNM4, ROGDI, LTBP3, FAM20C, CLDN16, CLDN19. Estos genes están implicados en la codificación de proteínas que participan en la fosforilación, intercambio de iones, y producción y degradación de los elementos constituyentes de la fase mineral y orgánica del esmalte dental. La evidencia científica confirma que la AI puede ser parte del síndrome y amerita una especial atención de la comunidad médica-odontológica.

Palabras clave:

amelogénesis imperfecta, esmalte dental, proteínas del esmalte dental, estética dental, genes, síndrome

Submitted: January 16/2018 - Accepted: August 28/2018



How to quote this article: Simancas-Escorcia V, Natera A, Acosta-de-Camargo MG. Genes involved in amelogenesis imperfecta. Part II. *Rev Fac Odontol Univ Antioq.* 2019; 30(2): 224-235. DOI: <http://dx.doi.org/10.17533/udea.rfo.v30n2a9>

INTRODUCTION

Dental enamel is an acellular, avascular, and non-inert structure consisting of a mineral phase and an organic form composed of structure proteins, lipids, phospholipids, enzymes, and water.¹ During enamel formation, there can be alterations of the enamel structure responsible for aesthetic and functional problems. One of these alterations is amelogenesis imperfecta (AI), a condition of genetic origin that impacts the structure of tooth enamel and can appear as a syndromic alteration or isolated. When the enamel alteration affects a group of teeth from both dentitions and there are systemic clinical manifestations, the etiological origin is likely due to genetic alterations.²

AI has an autosomal dominant, autosomal recessive, X- and Y-linked inheritance or sporadic pattern. According to the scarce epidemiological studies available, the prevalence of AI can vary from 1/700 to 1/14.000 in countries like Switzerland and the United States respectively.³ Alterations in the dental structure are usually widespread and affect all or most teeth. There are three forms of AI: hypoplastic, hypocalcified, and hypomaturation. Various AI classifications have been proposed, but the Witkop⁴ classification is still widely accepted as it includes aspects like phenotype, radiographic appearance, and mode of transmission.

The clinical manifestations of AI include loss of enamel translucency, tooth hypersensitivity, yellow, gray or brown pigmentation, and early attrition at the incisal level and at the cusps of molars. Dental eruption and gingival alterations are common, as well as

taurodontism; also, teeth with AI are more likely to be affected by carious processes as a result of biofilm retention.^{5,6} Given the importance of AI as an alteration of tooth enamel affecting patients of different age groups, our goal is to describe the genes and mutations involved in syndromic AI, the proteins encoded by these genes, and their functions according to current scientific evidence.

METHODS

An electronic literature search was conducted in the Medline (PubMed), EBSCOhost and Scopus (Science Direct) databases using the following keywords: amelogenesis imperfecta, genes AND/OR amelogenesis imperfecta, and syndrome AND/OR amelogenesis imperfecta. Full articles in English, accessible in PDF and produced from 2000 until December 2017 were obtained as inclusion criteria. No age or sex restrictions were used. Dissertations, newspapers, conferences, news, commentaries, and editorials were excluded.

The articles used in this literature review were collected and stored using the Zotero software, which also allowed to eliminate duplicate bibliographic references. The articles were independently evaluated by two reviewers according to the above criteria. Finally, a screening was conducted applying the criteria to the articles found in the databases, and 1,573 articles were preselected; of these, 40 met the inclusion criteria and were therefore analyzed and discussed (Table 1).

Table 1. Summary of the approach used for the electronic literature search

Keywords	Medline (PubMed)	EBSCOhost	Science Direct (Elsevier)
Amelogenesis imperfecta	262	400	219
Gene and/or Amelogenesis imperfecta	138	194	142
Syndrome and/or Amelogenesis imperfecta	53	92	73

Source: Simancas V, Natera A, Acosta MG

RESULTS

The results showed that mutations in 12 genes are responsible for syndromic AI. Below is a description of each gene.

Genes involved in syndromic amelogenesis imperfecta

1. DLX3

The *DLX3* gene (OMIM 600525, distal-less homeobox 3) has 3 exons and is located on chromosome 17, position 17q21.33. This gene encodes for a protein that is key in regulating the expression of osteocalcin during embryogenesis, along with *Dlx3*, *Dlx5*, *Msx2* and *Runx2*. *DLX3* has shown to be an enhancer in the expression of amelogenin and enameline. *DLX3* expresses in bones and dental tissues, particularly in odontoblasts and ameloblasts during the secretion stage.⁷

The *DLX3* gene mutation produces a hypomaturation-hypoplastic AI with broad pulp chambers and taurodontism. Indeed, this gene is reported to be the cause of the tricho-dento-osseous syndrome (TDO). TDO belongs to the ectodermal dysplasia group, characterized by curly hair from birth, enamel hypoplasia with discoloration and taurodontism in molars, overall increase in bone mineral density, and increased thickness in cortical skull bones.^{8,9}

Mutations in the *COL17A1*, *LAMA3*, *LAMB3* genes are responsible for junctional epidermolysis bullosa (JEB) and AI. JEB is a form of hereditary epidermolysis bullosa characterized by the formation of blistering lesions between dermis and epidermis, and by the healing of lesions with atrophy and/or formation of granulation tissue.¹⁰⁻¹²

2. COL17A1

The *COL17A1* gene (OMIM 113811, collagen, type XVII, alpha-1) is located in chromosome 10, position 10q24.3-q25.1. It has 56 exons and encodes for type XVII collagen. Nakamura et al¹³ reported two patients with JEB and a dental phenotype consistent with hypoplastic AI. The first patient had a deletion at position c.1.285 in exon 15 which resulted in the presence of a premature termination codon. This same patient also had a transition of cytosine to thymine at position c.4.264 in exon 53 that caused the conversion of codon CAG into a premature termination codon in amino acid 1.387. In the second patient, the *COL17A1* gene mutation occurred at position c.4.335 in exon 53, a deletion that led to the presence of a premature termination codon.

In a report describing different forms of JEB in the Netherlands caused by mutations in the *COL17A1* gene, Pasmooij et al¹⁴ identified five new deletions: 1.284delA, 1.365delC, 3.236delT, 3.600-3601delCT and 4.425delT.

Phenotypically, patients had hypoplastic AI and localized or widespread blisters on hands, feet, and face.

3. LAMA3

The *LAMA3* gene (OMIM 600805, laminin, alpha-3) consists of 75 exons and is located on chromosome 18, position 18q11.2. This gene encodes for laminin alpha-3, which is also a subunit of laminin 5. Mutations in this gene are related to non-syndromic and syndromic AI. In syndromic AI, mutations of the *LAMA3* gene are identified by a hypoplastic AI along with JEB. Gostyńska et al¹⁵ reported a nonsense mutation of the *LAMA3* gene (c.2.377C4T p. Arg793Ter) in a 2-year-old boy who since the age of 6 months developed blisters on hands, legs and ears, along with a hypoplastic AI. Yuen et al¹⁰ reported dental enamel defects related to hypoplastic AI in a mutation-carrying family in the *LAMA3* gene. The report showed the c.488delG mutation in exon 5, which produced a reading frame change and consequently a premature termination codon (p. G163DfsX30). The mutation c.4.484C>T in exon 33 of the *LAMA3* gene—which induces a replacement of alanine to valine at position 1.495 p. A1.495V—was also reported.

4. LAMB3

The *LAMB3* gene (OMIM 150310, laminin, beta-3) is composed of 23 exons and is located on chromosome 1, position 1q32.2. This gene encodes a protein known as laminin beta-3, a subunit of laminin 5. It acts at the transmembrane (in the basal membrane) and participates in cell growth and adhesion.¹⁶ It has been established that the mutations of the *LAMB3* gene are responsible for syndromic and non-syndromic AI. Within

the syndromic AI, changes in the *LAMB3* gene are also responsible for the presence of AI and JEB. Clinically, patients have internal skin blisters caused by an alteration in the formation of hemidesmosomes between the epidermis and basal lamina, along with enamel defects of varying severity.¹²

5. FAM20A

The *FAM20A* gene (OMIM 611062, family with sequence similarity 20, member A) has 11 exons and is located on chromosome 17, position 17q24.2. *FAM20A* is a gene belonging to the family with similarity in sequence 20, called *FAM20*, as well as *FAM20B* and *FAM20C*.¹⁷ Recently, Cui et al^{18,19} demonstrated that *FAM20A* enhances the activity of the protein kinase *FAM20C* which promotes the phosphorylation of proteins in the enamel matrix in vitro. According to Ohyama et al,²⁰ *FAM20A* is a pseudo-kinase that forms a functional complex with *FAM20C*, and thanks to this functional complex, *FAM20C* increases its phosphorylation capacity. As a result, mutations of the *FAM20A* gene contribute to deregulation of the cellular microenvironment of calcium and/or phosphate by favoring an alteration of the regulatory processes of mineralization.²¹

The autosomal recessive mutation in the *FAM20A* gene is responsible for the Amelogenesis Imperfecta-Nephrocalcinosis Syndrome, also known as Enamel-Renal Syndrome (ERS - OMIM 204690) which associates a hypoplastic AI with nephrocalcinosis. This syndrome affects both deciduous and permanent teeth. In addition to hypoplastic AI, this syndrome has other clinical conditions, including gingival hyperplasia, alterations in teeth eruption, relative microdontia, spaced-out teeth,

intrapulp calcification, dilation of impacted teeth roots, and ectopic calcification of dental and gum follicles, coupled with nephrocalcinosis.²²

6. TP63

The *TP63* gene (OMIM 603273, tumor protein P63) has 14 exons and is located on chromosome 3, position 3q28. It is responsible for the coding of an essential transcription factor that initiates ectodermal development, as well as limb and tooth development. This transcription factor is secreted by epithelial cells and is involved in the transfer of signals to the ectomesenchymal cells.²³

TP63 mutations have been linked to the ectrodactyly-ectodermal dysplasia clefting syndrome (EEC syndrome), a genetic developmental disorder characterized by ectrodactyly, ectodermal dysplasia, and orofacial clefts (cleft lip/palate).^{23,24} Kantaputra et al²⁵ reported on a family with a nonsense heterozygous mutation in intron 4 of the *TP63* gene where, in addition to ectodermal dysplasia and ectrodactyly, one of the patients showed supernumerary premolars, incisor fusion and hypoplastic, hypocalcified and hypomaturation AI.

7. CNNM4

The *CNNM4* gene (OMIM 607805, cyclin protein M4) is composed of 7 exons and is located on chromosome 2, position 2q11.2. This gene encodes a protein of 775 amino acids involved in the transport of metal ions, most likely magnesium (Mg), essential for the proper functioning of photoreceptors in the retina. *CNNM4* is expressed in the ameloblasts and odontoblasts, and therefore

its presence is fundamental in the formation of tooth-enamel crystals.^{26,27}

Autosomal recessive mutations of the *CNNM4* gene result in the Jalili Syndrome, characterized by a combination of hypoplastic and/or hypocalcified AI, along with cone-rod dystrophy. The enamel appears cracked and rough with a yellow coloration. An anterior open bite and taurodontism of the molars are also common. The cone-rod dystrophy, on the other hand, causes central vision loss, color vision defects, and photophobia long before the age of 10.^{28,29}

8. ROGDI

The *ROGDI* gene (OMIM 614574, *ROGDI* homologous of *Drosophila* OG) has 7 exons and is located on chromosome 16, position 16p13.3. It encodes for a leucine zipper domain protein. The role of the *ROGDI* protein is still unknown, but it is known to interact with MAP kinase (mitogen-activating protein) in the cell cycle. Also, *ROGDI* interacts with *DISC1*, a protein involved in cytoskeleton stability, neuronal migration, intracellular transport and cell division.^{30,31}

As a result of an autosomal recessive mutation, the *ROGDI* gene is responsible for amelo-cerebro-hypohidrotic syndrome or Kohlschütter-Tönz Syndrome, a degenerative disorder characterized by AI, convulsions, and yellow teeth due to enamel defects. Its clinical manifestations may be limited to cognitive problems, speech delay and learning problems, or may be associated with psychomotor delay, spasticity and epilepsy. In the mouth, it shows a hypocalcified-hypoplastic AI along with a very thin enamel.^{32,33}

9. *LTBP3*

The *LTBP3* gene (OMIM 602090 latent transforming growth factor-beta-binding protein 3) has 28 exons; it is located on chromosome 11, position 11q13.1 and encodes for a protein of the TGF-beta signaling pathway, involved in the production and degradation of the extracellular matrix. The autosomal recessive mutation of the *LTBP3* gene produces brachyolmia-amelogenesis imperfecta. This pathology is part of a heterogeneous group of skeletal dysplasia characterized by a short stature and a short trunk. A hypoplastic AI with taurodontism and wide pulp chambers, delayed dental eruption, and oligodontia are part of the phenotypic characteristics of these patients.³⁴⁻³⁶

10. *FAM20C*

The *FAM20C* gene (OMIM 611061, family with sequence similarity 20, member C) consists of 10 exons. Located on chromosome 7, position 7p22.3, *FAM20C* is a gene belonging to the family with sequence similarity 20, called FAM20, which encodes for a casein kinase of the golgi apparatus responsible for phosphorylating enamel proteins (amelogenins, enamelines and ameloblastins), osteopontin, and a large amount of proteins involved in various physiological processes.³⁷⁻³⁹

The recessive *FAM20C* mutation leads to Raine Syndrome, a condition characterized by a hypophosphatemia disorder, generalized osteosclerosis, periosteal ossification, facial dimorphism, and intracerebral abnormalities. Gingival hyperplasia, bifid uvula, cleft palate, and hypoplastic AI are part of the oral phenotype. It was initially considered a lethal pathology at an early age, but patient survival into adulthood has been reported.⁴⁰

11. *CLDN16*

The *CLDN16* gene (OMIM 603959, claudin 16) has 5 exons and is located on chromosome 3, position 3q28. It encodes for a protein that plays a central role in the reabsorption of divalent cations in the tight junctions of renal epithelial cells of the ascending limb of Henle, where it forms selective cation pores that facilitate the reabsorption of Ca^{2+} and Mg^{2+} .^{41,42}

The *CLDN16* mutation is responsible for familial primary hypomagnesaemia with hypercalciuria and nephrocalcinosis (FHHN), a form of familial primary hypomagnesaemia characterized by recurrent urinary tract infections, nephrolithiasis, bilateral nephrocalcosis, renal loss of Ca^{2+} and Mg^{2+} , hypercalciuria and kidney failure. Recently, Bardet et al⁴³ demonstrated the expression of *CLDN16* in dental germ, showing that mutations of this gene are responsible for AI in the 5 FHHNC studied patients. The dental examination showed that all patients had enamel defects, including a decrease in the amount of enamel; in fact, four patients had hypoplastic AI and one of them had hypomaturational AI.

12. *CLDN19*

The *CLDN19* gene (OMIM 610036, claudin 19) has 5 exons and is located on chromosome 1, position 1q34.2. It is responsible for encoding transmembrane proteins found in tight junctions of renal epithelial cells just like *CLDN16*. These junctions form barriers that control the passage of ions and molecules through epithelial sheets and the movement of proteins and lipids between the apical and basolateral domains of epithelial cells.⁴⁴

Like mutations in the *CLDN16* gene, the *CLDN19* mutation is responsible for familial primary hypomagnesaemia with

hypercalciuria and nephrocalcinosis. In 2017, Yamaguti et al⁴⁵ reported six families unrelated to *CLDN19* mutations. Clinically, a hypoplastic AI with nearly complete absence of enamel, crown dysmorphology, dark brown teeth, and enamel fractures were described.

A summarizing table displays information regarding the known genes involved in AI (Table 2), while Figure 3 shows the function of proteins encoded by those genes according to anatomical compartment during tooth enamel formation.

Table 2. Genes involved in syndromic amelogenesis imperfecta

Gene (OMIM)	Position	Number of exons Transmission	Encoded protein	AI type/associated syndrome
<i>DLX3</i> (distal-less homeobox 3) OMIM 600525	17q21.33	3-AD	Transcription factor	Hypoplastic and Hypomaturation / trichodento-osseous syndrome (TDO)
<i>COL17A1</i> (collagen, type XVII, alpha-1) OMIM 113811	10q24,3-q25.1	56-AD	Collagen, type XVII, alpha1	Hypoplastic / Junctional Epidermolysis Bullosa (JEB)
<i>LAMA3</i> (laminin, alpha-3) OMIM 600805	18q11.2	75 -AR	Laminin, alpha-3	Hypoplastic / Junctional Epidermolysis Bullosa (JEB)
<i>LAMB3</i> (laminin, beta-3) OMIM 150310	1q32.2	23-AR	Laminin, beta-3	Hypoplastic / Junctional Epidermolysis Bullosa (JEB)
<i>FAM20A</i> (family with sequence similarity 20, member A) OMIM 611062	17q24.2	11-AR	Secreted pseudokinase	Hypoplastic / Amelogenesis imperfecta Nephrocalcinosis Syndrome or Enamel-Renal Syndrome (ERS)
<i>TP63</i> (tumor protein P63) OMIM 603273	3q28	14-AD	Transcription factor	Hypoplastic, hypomaturation and hypocalcified / Ectrodactyly-Ectodermal Dysplasia Clefting Syndrome (ECC)
<i>CNNM4</i> (cyclin protein M4) OMIM 607805	2q11.2	7-AR	Metal transporter	Hypoplastic and hypocalcified / Jalili Syndrome
<i>ROGDI</i> (ROGDI homologous of Drosophila OG) OMIM 614574	16p13.3	7-AR	Unknown functional role	Hypocalcified and hypomaturation / Amelo-cerebro-hypohidrotic syndrome or Kohlschütter-Tönz Syndrome
<i>LTBP3</i> (Latent-transforming growth factor beta-binding protein 3) OMIM 602090	11q13.1	28-AR	Production and degradation of extracellular matrix	Hypoplastic with taurodontism / Brachyolmia
<i>FAM20C</i> (family with sequence similarity 20, member C) OMIM 611061	7p22.3	10-AR	Protein kinase	Hypoplastic / Raine Syndrome
<i>CLDN16</i> (Claudin 16) OMIM 603959	3q28	5-AR	Tight joints of renal epithelial cells	Hypoplastic and hypomature / Familial primary hypomagnesaemia with hypercalciuria and nephrocalcinosis (FHHN)
<i>CLDN19</i> (claudin 19) OMIM 610036	1q34.2	5-AR	Tight joints of renal epithelial cells	Hypoplastic / Familial primary hypomagnesaemia with hypercalciuria and nephrocalcinosis (FHHN)

AD: autosomal dominant; AR: autosomal recessive

Source: Simancas V, Natera A, Acosta MG

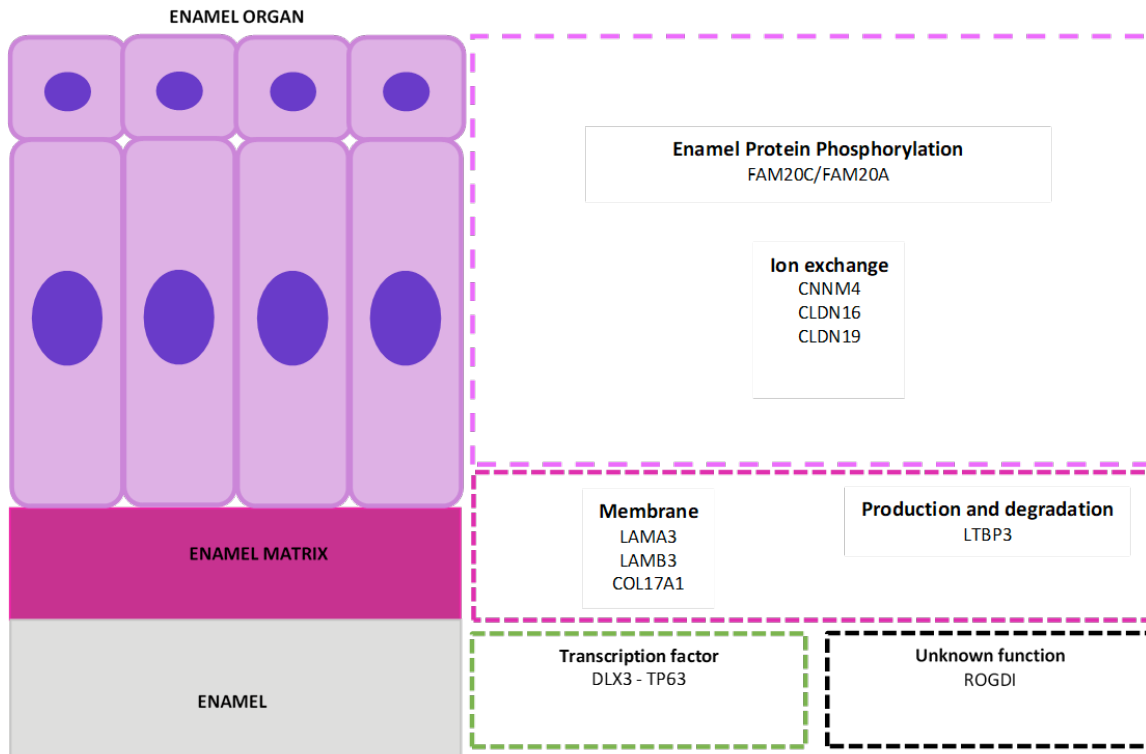


Figure 3. Function of the proteins encoded by genes involved in amelogenesis imperfecta

The enamel organ with ameloblastic cell area (purple), enamel matrix (violet), and enamel (grey). In the lower area, the transcription factors (green box) and genes responsible for amelogenesis imperfecta with no currently known function at the dental level (black box).

Source: Simancas V, Natera A, Acosta MG.

CONCLUSIONS

Observation of the bucco-dental and systemic phenotype remains a good indicator in human genetics research. This literature review showed that 12 genes are responsible for syndromic AI, including genes *DLX3*, *COL17A1*, *LAMA3*, *LAMB3*, *FAM20A*, *TP63*, *CNNM4*, *ROGDI*, *LTBP3*, *FAM20C*, *CLDN16*, *CLDN19*. These genes participate in the coding of proteins involved in phosphorylation, ion exchange, production and degradation of constituent elements of the mineral and organic phases of tooth enamel.

In the presence of a phenotype compatible with AI and systemic alterations, a probable

genetic origin should be confirmed. For this reason, comprehensive clinical, radiographic and genetic examinations of parents and siblings are recommended, as it will help establish a family tree to specify the mode of transmission. The clinical and radiographic evaluation of kidneys, lungs, vertebrae, and vascular system will help diagnose a syndromic or non-syndromic AI.

ACKNOWLEDGMENTS

To the program Bolívar Gana con Ciencia, of Gobernación de Bolívar, Colombia, and Fundación Ceiba for accompanying and providing partial financing for this project.

We also express our gratitude to Dr. Dominique Hotton, of the Laboratory of Oral Molecular Pathophysiology of Université Paris-Diderot, for her support to this project.

CONFLICT OF INTEREST

The authors declare that they have no conflict of interest.

CORRESPONDING AUTHOR

Víctor Simancas-Escorcía
Universidad de Cartagena
(+575) 669 8172 Ext. 124
Fax (+575) 669 8173 Ext. 124
vsimancasescorcia@hotmail.com
Calle 30 #48 -152. Barrio Zaragocilla,
Cartagena de Indias, Colombia

REFERENCES

1. Zheng L, Ehardt L, McAlpin B, About I, Kim D, Papagerakis S, et al. The tick tock of odontogenesis. *Exp Cell Res.* 2014 Jul 15; 325(2): 83–9. DOI: <https://doi.org/10.1016/j.yexcr.2014.02.007>
2. Prasad MK, Geoffroy V, Vicaire S, Jost B, Dumas M, Le Gras S, et al. A targeted next-generation sequencing assay for the molecular diagnosis of genetic disorders with orodental involvement. *J Med Genet.* 2016 Feb; 53(2): 98–110. DOI: <http://dx.doi.org.gate2.inist.fr/10.1136/jmedgenet-2015-103302>
3. Crawford PJM, Aldred M, Bloch-Zupan A. Amelogenesis imperfecta. *Orphanet J Rare Dis.* 2007 Apr 4; 2:17. DOI : <https://doi.org/10.1186/1750-1172-2-17>
4. Witkop CJ. Amelogenesis imperfecta, dentinogenesis imperfecta and dentin dysplasia revisited: problems in classification. *J Oral Pathol.* 1988 Nov; 17(9-10): 547–53. DOI: <https://doi.org/10.1111/j.1600-0714.1988.tb01332.x>
5. Oliveira AFB, Chaves AMB, Rosenblatt A. The influence of enamel defects on the development of early childhood caries in a population with low socioeconomic status: a longitudinal study. *Caries Res.* 2006; 40(4): 296–302. DOI: <https://doi-org.gate2.inist.fr/10.1159/000093188>
6. Uribe S. Early childhood caries–risk factors. *Evid Based Dent.* 2009; 10(2): 37–8. DOI: <https://doi-org.gate2.inist.fr/10.1038/sj.ebd.6400642>
7. Zhang Z, Tian H, Lv P, Wang W, Jia Z, Wang S, et al. Transcriptional factor DLX3 promotes the gene expression of enamel matrix proteins during amelogenesis. *PloS One.* 2015; 10(3): e0121288. DOI : <https://doi.org/10.1371/journal.pone.0121288>
8. Nieminen P, Lukinmaa P-L, Alapulli H, Methuen M, Suojärvi T, Kivirikko S, et al. DLX3 homeodomain mutations cause tricho-dento-osseous syndrome with novel phenotypes. *Cells Tissues Organs.* 2011; 194(1): 49–59. DOI: <https://doi-org.gate2.inist.fr/10.1159/000322561>
9. Kim Y-J, Seymen F, Koruyucu M, Kasimoglu Y, Gencay K, Shin TJ, et al. Unexpected identification of a recurrent mutation in the DLX3 gene causing amelogenesis imperfecta. *Oral Dis.* 2016 May; 22(4): 297–302. DOI : <https://doi-org.gate2.inist.fr/10.1111/odi.12439>
10. Yuen WY, Pasmooij AMG, Stellingsma C, Jonkman MF. Enamel defects in carriers of a novel LAMA3 mutation underlying epidermolysis bullosa. *Acta Derm Venereol.* 2012 Nov; 92(6): 695–6. DOI: 10.2340/00015555-1341
11. McGrath JA, Gatalica B, Li K, Dunnill MG, McMillan JR, Christiano AM, et al. Compound heterozygosity for a dominant glycine substitution and a recessive internal duplication mutation in the type XVII collagen

- gene results in junctional epidermolysis bullosa and abnormal dentition. *Am J Pathol.* 1996 Jun; 148(6): 1787–96.
12. Wright JT, Johnson LB, Fine JD. Development defects of enamel in humans with hereditary epidermolysis bullosa. *Arch Oral Biol.* 1993 Nov; 38(11): 945–55. DOI: 10.1016/0003-9969(93)90107-w
 13. Nakamura H, Sawamura D, Goto M, Nakamura H, Kida M, Ariga T, et al. Analysis of the COL17A1 in non-Herlitz junctional epidermolysis bullosa and amelogenesis imperfecta. *Int J Mol Med.* 2006 Aug; 18(2): 333–7. DOI: <https://doi.org/10.3892/ijmm.18.2.333>
 14. Pasmooij AMG, Pas HH, Jansen GHL, Lemmink HH, Jonkman MF. Localized and generalized forms of blistering in junctional epidermolysis bullosa due to COL17A1 mutations in the Netherlands. *Br J Dermatol.* 2007 May; 156(5): 861–70. DOI: <https://doi.org/10.1111/j.1365-2133.2006.07730.x>
 15. Gostyńska KB, Yuen WY, Pasmooij AMG, Stellingsma C, Pas HH, Lemmink H, et al. Carriers with functional null mutations in *LAMA3* have localized enamel abnormalities due to haploinsufficiency. *Eur J Hum Genet.* 2017 Jan; 25(1): 94–9. DOI: <https://doi.org/10.1038/ejhg.2016.136>
 16. Wang X, Zhao Y, Yang Y, Qin M. Novel ENAM and LAMB3 mutations in Chinese families with hypoplastic amelogenesis imperfecta. *PloS One.* 2015; 10(3): e0116514. DOI: <https://doi.org/10.1371/journal.pone.0116514>
 17. Nalbant D, Youn H, Nalbant SI, Sharma S, Cobos E, Beale EG, et al. FAM20: an evolutionarily conserved family of secreted proteins expressed in hematopoietic cells. *BMC Genomics.* 2005 Jan 27; 6:11. DOI: <https://doi.org/10.1186/1471-2164-6-11>
 18. Cui J, Xiao J, Tagliabracci VS, Wen J, Rahdar M, Dixon JE. A secretory kinase complex regulates extracellular protein phosphorylation. *eLife.* 2015 Mar 19; 4:e06120. DOI: <https://doi.org/10.7554/eLife.06120.001>
 19. Cui J, Zhu Q, Zhang H, Cianfrocco MA, Leschziner AE, Dixon JE, et al. Structure of Fam20A reveals a pseudokinase featuring a unique disulfide pattern and inverted ATP-binding. *eLife.* 2017 22; 6. DOI: <https://doi.org/10.7554/eLife.23990.001>
 20. Ohyama Y, Lin J-H, Govitvattana N, Lin I-P, Venkitapathi S, Alamoudi A, et al. FAM20A binds to and regulates FAM20C localization. *Sci Rep.* 2016 13; 6:27784. DOI: <https://doi.org/10.1038/srep27784>
 21. Lignon G, Beres F, Quentric M, Rouzière S, Weil R, De La Dure-Molla M, et al. FAM20A Gene Mutation: Amelogenesis or Ectopic Mineralization? *Front Physiol.* 2017; 8:267. DOI: <https://doi.org/10.3389/fphys.2017.00267>
 22. de la Dure-Molla M, Quentric M, Yamaguti PM, Acevedo A-C, Mighell AJ, Vikkula M, et al. Pathognomonic oral profile of Enamel Renal Syndrome (ERS) caused by recessive FAM20A mutations. *Orphanet J Rare Dis.* 2014 Jun 14; 9:84. DOI: <https://doi.org/10.1186/1750-1172-9-84>
 23. Yang A, Kaghad M, Wang Y, Gillett E, Fleming MD, Dötsch V, et al. p63, a p53 homolog at 3q27-29, encodes multiple products with transactivating, death-inducing, and dominant-negative activities. *Mol Cell.* 1998 Sep; 2(3): 305–16. DOI: [https://doi.org/10.1016/S1097-2765\(00\)80275-0](https://doi.org/10.1016/S1097-2765(00)80275-0)
 24. Alves LU, Pardono E, Otto PA, Mingroni Netto RC. A novel c.1037C > G (p.Ala346Gly) mutation in TP63 as cause of the ectrodactyly-ectodermal dysplasia and cleft lip/palate (EEC) syndrome. *Genet Mol Biol.* 2015 Mar; 38(1): 37–41. DOI: 10.1590/S1415-475738120140125
 25. Kantaputra PN, Matangkasombut O, Sripathomsawat W. Split hand-split foot-ectodermal dysplasia and amelogenesis imperfecta with a TP63 mutation. *Am J Med Genet A.* 2012 Jan; 158A(1): 188–92. DOI: <https://doi.org/10.1002/ajmg.a.34356>

26. Luder HU, Gerth-Kahlert C, Ostertag-Benzinger S, Schorderet DF. Dental phenotype in Jalili syndrome due to a c.1312 dupC homozygous mutation in the CNNM4 gene. *PloS One*. 2013; 8(10): e78529. DOI: <https://doi.org/10.1371/journal.pone.0078529>
27. Cherkaoui Jaouad I, Lyahyai J, Guaoua S, El Alloussi M, Zrhidri A, Doubaj Y, et al. Novel splice site mutation in CNNM4 gene in a family with Jalili syndrome. *Eur J Med Genet*. 2017 May; 60(5): 239–44. DOI: <https://doi.org/10.1016/j.ejmg.2017.02.004>
28. Jalili IK. Cone-rod dystrophy and amelogenesis imperfecta (Jalili syndrome): phenotypes and environs. *Eye Lond Engl*. 2010 Nov; 24(11): 1659–68. DOI: <https://doi.org/10.1038/eye.2010.103>
29. Topçu V, Alp MY, Alp CK, Bakır A, Geylan D, Yılmazoğlu MÖ. A new familial case of Jalili syndrome caused by a novel mutation in CNNM4. *Ophthalmic Genet*. 2017 Apr; 38(2): 161–6. DOI: <https://doi-org.gate2.inist.fr/10.3109/13816810.2016.1164192>
30. Schossig A, Wolf NI, Fischer C, Fischer M, Stocker G, Pabinger S, et al. Mutations in ROGDI Cause Kohlschütter-Tönz Syndrome. *Am J Hum Genet*. 2012 Apr 6; 90(4): 701–7. DOI: <https://doi.org/10.1016/j.ajhg.2012.02.012>
31. Schossig A, Wolf NI, Kapferer I, Kohlschütter A, Zschocke J. Epileptic encephalopathy and amelogenesis imperfecta: Kohlschütter-Tönz syndrome. *Eur J Med Genet*. 2012 May; 55(5): 319–22. DOI: <https://doi.org/10.1016/j.ejmg.2012.02.008>
32. Aswath N, Ramakrishnan SN, Teresa N, Ramanathan A. A novel ROGDI gene mutation is associated with Kohlschütter-Tönz syndrome. *Oral Surg Oral Med Oral Pathol Oral Radiol*. 2018 Jan; 125(1): e8–11. DOI: <https://doi.org/10.1016/j.o000.2017.09.016>
33. Huckert M, Mecili H, Laugel-Haushalter V, Stoetzel C, Muller J, Flori E, et al. A Novel Mutation in the ROGDI Gene in a Patient with Kohlschütter-Tönz Syndrome. *Mol Syndromol*. 2014 Dec; 5(6): 293–8. DOI: <https://doi-org.gate2.inist.fr/10.1159/000366252>
34. Verloes A, Jamblin P, Koulischer L, Bourguignon JP. A new form of skeletal dysplasia with amelogenesis imperfecta and platyspondyly. *Clin Genet*. 1996 Jan; 49(1): 2–5. DOI: <https://doi-org.gate2.inist.fr/10.1111/j.1399-0004.1996.tb04315.x>
35. Huckert M, Stoetzel C, Morkmued S, Laugel-Haushalter V, Geoffroy V, Muller J, et al. Mutations in the latent TGF-beta binding protein 3 (LTBP3) gene cause brachyolmia with amelogenesis imperfecta. *Hum Mol Genet*. 2015 Jun 1; 24(11): 3038–49. DOI: <https://doi-org.gate2.inist.fr/10.1093/hmg/ddv053>
36. Dugan SL, Temme RT, Olson RA, Mikhailov A, Law R, Mahmood H, et al. New recessive truncating mutation in LTBP3 in a family with oligodontia, short stature, and mitral valve prolapse. *Am J Med Genet A*. 2015 Jun; 167(6): 1396–9. DOI: <https://doi-org.gate2.inist.fr/10.1002/ajmg.a.37049>
37. Tagliabracci VS, Engel JL, Wen J, Wiley SE, Worby CA, Kinch LN, et al. Secreted kinase phosphorylates extracellular proteins that regulate biomineralization. *Science*. 2012 Jun 1; 336(6085): 1150–3. DOI: [10.1126/science.1217817](https://doi.org/10.1126/science.1217817)
38. Pollak AJ, Haghghi K, Kunduri S, Arvanitis DA, Bidwell PA, Liu G-S, et al. Phosphorylation of serine96 of histidine-rich calcium-binding protein by the Fam20C kinase functions to prevent cardiac arrhythmia. *Proc Natl Acad Sci U S A*. 2017 22; 114(34): 9098–103. DOI: <https://doi-org.gate2.inist.fr/10.1073/pnas.1706441114>
39. Oya K, Ishida K, Nishida T, Sato S, Kishino M, Hirose K, et al. Immunohistochemical analysis of dentin matrix protein 1 (Dmp1) phosphorylation by Fam20C in bone: implications for the induction of biomineralization. *Histochem Cell Biol*. 2017 Mar; 147(3): 341–51. DOI: <https://doi.org/10.1007/s00418-016-1490-z>

40. Acevedo AC, Poulter JA, Alves PG, de Lima CL, Castro LC, Yamaguti PM, et al. Variability of systemic and oro-dental phenotype in two families with non-lethal Raine syndrome with FAM20C mutations. *BMC Med Genet.* 2015 Feb 21; 16:8. DOI: <https://doi.org/10.1186/s12881-015-0154-5>
41. Hou J, Renigunta A, Gomes AS, Hou M, Paul DL, Waldegger S, et al. Claudin-16 and claudin-19 interaction is required for their assembly into tight junctions and for renal reabsorption of magnesium. *Proc Natl Acad Sci U S A.* 2009 Sep 8; 106(36): 15350–5. DOI: <https://doi-org.gate2.inist.fr/10.1073/pnas.0907724106>
42. Günzel D, Yu ASL. Claudins and the modulation of tight junction permeability. *Physiol Rev.* 2013 Apr; 93(2): 525–69. DOI: <https://doi-org.gate2.inist.fr/10.1152/physrev.00019.2012>
43. Bardet C, Courson F, Wu Y, Khaddam M, Salmon B, Ribes S, et al. Claudin-16 Deficiency Impairs Tight Junction Function in Ameloblasts, Leading to Abnormal Enamel Formation. *J Bone Miner Res Off J Am Soc Bone Miner Res.* 2016 Mar; 31(3): 498–513. DOI: <https://doi-org.gate2.inist.fr/10.1002/jbmr.2726>
44. Lee NPY, Tong MK, Leung PP, Chan VW, Leung S, Tam P-C, et al. Kidney claudin-19: localization in distal tubules and collecting ducts and dysregulation in polycystic renal disease. *FEBS Lett.* 2006 Feb 6; 580(3): 923–31. DOI: <https://doi-org.gate2.inist.fr/10.1016/j.febslet.2006.01.019>
45. Yamaguti PM, Neves F de AR, Hotton D, Bardet C, de La Dure-Molla M, Castro LC, et al. Amelogenesis imperfecta in familial hypomagnesaemia and hypercalciuria with nephrocalcinosis caused by CLDN19 gene mutations. *J Med Genet.* 2017; 54(1): 26–37. DOI: <http://dx.doi.org.gate2.inist.fr/10.1136/jmedgenet-2016-103956>