

Gastric Ulcers Syndrome in Donkeys

Abelardo Morales Briceño¹ / Antonio Lamprea Garrido² / Aniceto Méndez Sánchez³

Abstract

This study aimed to describe gastric ulcer in donkeys. 10 donkeys (*Equus asinus*) were studied in Bodonal de la Sierra, Badajoz-Extremadura, Spain. They were referred for necropsy and dead due to non-digestive causes. 4 males and 6 females were examined. The ages were classified of 4-16 years old. The stomach and gastric mucosa was evaluated for classified Merit, 2003. Samples of gastric tissue were collected. The samples fixed in formalin were processed by conventional histological techniques and examined by histopathology. None of the donkeys presented clinical signs for gastric ulcers syndrome. Of the 10 donkeys studied, 10% had Grade 0; 30% Grade 1; 40% Grade 2; 10% Grade 3; and 10% Grade 4. In 30% (3/10) parasites such as *Gasterophilus* sp. were observed. The histological slices revealed severe damage on the gastric mucosa, a loss of continuity of the gastric mucosa with corium exposure, and subchorionic edema with parakeratotic hyperkeratosis, together with a mixed lymphoplasmocytic mononuclear infiltrate. In conclusion, we reported gastric ulcers syndrome in donkeys in Spain.

Keywords: EGUS, donkey, gastritis, ulcer.

- 1 Zoosanitarios de la Sierra S.L. Fregenal de la Sierra, Badajoz-Extremadura, Spain. Department of Anatomy and Comparative Anatomic Pathology, College of Veterinary Medicine. University of Córdoba, Spain. Edificio de Sanidad Animal, Campus de Rabanales Ctra. de Madrid km 396, 14071, Córdoba, Spain.
✉ aamorales13@gmail.com
- 2 Zoosanitarios de la Sierra S.L. Fregenal de la Sierra, Badajoz-Extremadura, Spain.
✉ zoosierra@hotmail.com
- 3 Department of Anatomy and Comparative Anatomic Pathology, College of Veterinary Medicine. University of Córdoba, Spain.
✉ an1mesaa@uco.es

Síndrome de úlcera gástrica en burros

Resumen

Este estudio tuvo como objetivo describir la úlcera gástrica en burros. Se estudiaron 10 burros (*Equus asinus*) en Bodonal de la Sierra, Badajoz-Extremadura, España. Fueron remitidos para necropsia y muertos debido a causas no digestivas. Se examinaron 4 machos y 6 hembras. Las edades estuvieron comprendidas entre los 4 y los 16 años de edad. El estómago y la mucosa gástrica se analizaron con la clasificación de Merri, 2003. Se recogieron muestras de tejido gástrico, se fijaron en formol y se procesaron con técnicas histológicas convencionales. Luego se examinaron por histopatología. Ningún burro presentó los signos clínicos del síndrome de úlcera gástrica. De los 10 burros estudiados, el 10% tenía grado 0; el 30%, grado 1; el 40%, grado 2; el 10%, grado 3, y 10%, grado 4. En el 30% (3/10) se observaron parásitos tipo *Gasterophilus* sp. Los cortes histológicos revelaron graves daños en la mucosa gástrica, una pérdida de continuidad de la mucosa gástrica (con exposición de la dermis) y edema subcoriónico con hiperqueratosis paraqueratósica, junto con un infiltrado mononuclear linfoplasmocítico mixto. En conclusión, se reportó el síndrome de úlcera gástrica en burros en España.

Palabras clave: síndrome de úlcera gástrica en equinos, burros, gastritis, úlcera.

How to cite this article: Morales Briceño A, Lamprea Garrido A, Méndez Sánchez A. Gastric ulcers syndrome in donkeys. Rev Med Vet. 2015;(30):31-5.

Síndrome de úlcera gástrica em burros

Resumo

Este estudo teve como objetivo descrever a úlcera gástrica em burros. Foram realizados estudos em 10 burros (*Equus asinus*) em Bodonal de La Sierra, Badajoz-Extremadura, Espanha. Foram remitidos para necropsia e mortos devido a causas não digestivas. Examinaram-se 4 machos e 6 fêmeas. As idades estiveram compreendidas entre os 4 e os 16 anos de idade. O estômago e a mucosa gástrica foram analisados com a classificação de Merri, 2003. Recolheram-se amostras de tecido gástrico, se fixaram em formol e se processaram com técnicas histológicas convencionais. Depois se examinaram por histologia patológica. Nenhum burro apresentou os sinais clínicos da síndrome de úlcera gástrica. Dos 10 burros estudados, o 10% tinha grau 0; o 30%, grau 1; o 40%, grau 2; o 10%, grau 3, e 10%, grau 4. Em 30% (3/10) se observaram parasitas tipo *Gasterophilus* sp. Os cortes histológicos revelaram graves danos na mucosa gástrica, uma perda de continuidade da mucosa gástrica (com exposição da derme) e hematoma subcoriônico com hiperqueratose paraqueratósica, junto com um infiltrado mononuclear linfoplasmocítico misto. Em conclusão, foi reportada a síndrome de úlcera gástrica em burros na Espanha.

Palavras chave: síndrome de úlcera gástrica em equinos, burros, gastrite, úlcera.

INTRODUCTION

Equine gastric ulcers syndrome (EGUS) is characterized by ulceration in the terminal esophagus, proximal (squamous) stomach, distal (glandular) stomach, and proximal duodenum (1). Gastric ulcers are highly prevalent in horses (1-4). The equine gastric ulcers syndrome (EGUS) has been described in several horse breeds, but not much has been reported in donkeys. The diagnosis of EGUS is based on history, clinical signs, endoscopic examination, and response to treatment. All ages and breeds of horses are susceptible to EGUS; intermittent mild colic signs, especially during and after eating, can be a sign of this disease (1). Clinical signs associated with EGUS are numerous and often vague. Acute and recurrent colic, diarrhea, rough hair coat, poor appetite, weight loss, attitude changes, depression, and decreased performance are seen in horses with gastric ulcers (1,3). Although EGUS has long been identified, its etiology usually remains unknown because of the lack of multidisciplinary studies (5,6). This study aimed to describe gastric ulcer in donkeys.

MATERIALS AND METHODS

10 asymptomatic donkeys (*Equus asinus*) were studied in Bodonal de la Sierra, Badajoz-Extremadura, Spain. They were referred for necropsy (7) and dead due to non-digestive causes. In relation to sex: 4 males and 6 females were examined. The ages were classified of 4-16 years old, Andalusian race. The stomach and gastric mucosa was evaluated for classified Merrit, 2003 (3). Grade 0: Epithelium is intact throughout; no hyperemia, no hyperkeratosis (yellowish color, sloughing). Grade 1: Mucosa is intact but there are areas of hyperemia and/or hyperkeratosis. Grade 2: Small, single or multi-focal erosion or ulcer. Grade 3: Large, single or multi-focal ulcers, or extensive erosions and sloughing. Grade 4: Extensive ulcers, with areas of deep submucosal penetration. Samples of gastric tissue were collected. The samples fixed in formalin were processed by conventional histological techniques (dehydration, inclusion in paraffin, microtome slicing, and routine staining with Hematoxylin-eosin) and examined by histopathology (8).

RESULTS

From the 10 donkeys studied, 10% had (1/10) Grade 0: Epithelium is intact throughout; no hyperemia, no hyperkeratosis (yellowish color, sloughing) (Figure 1). Grade 1: Mucosa is intact but there are areas of hyperemia and/or hyperkeratosis was found in 30% (3/10). Grade 2, in 40% (4/10); Grade 3, in 10% (1/10) (Figure 3); and Grade 4, in 10% (1/10) (Figure 4). In 30% (3/10) parasites such as *Gasterophilus* sp. were observed (Figure 2). The region most affected corresponds to the squamous-glandular transition in the margo plicatus. In general, the histological slices revealed severe damage on the gastric mucosa, a loss of continuity of the gastric mucosa with corium exposure, and subchorionic edema with parakeratotic hyperkeratosis, together with a mixed lymphoplasmocytic mononuclear infiltrate. Specifically, in 10% the epithelium is intact throughout, with no hyperemia, nor hyperkeratosis. The mucosa is intact but there are areas of hyperemia and/or hyperkeratosis in 30%. There are small, single or multi-focal erosions or ulcers in 40%, infiltrated of lymphocytes in lamina propria. There are large, single or multi-focal ulcers, or extensive erosions and sloughing in 10%, infiltrated of lymphocytes in lamina propria. Finally, extensive ulcers, with areas of deep submucosal penetration, infiltrated of lymphocytes in lamina propria with exposition of corium were observed in 10%.

Figure 1. Donkey stomach, normal

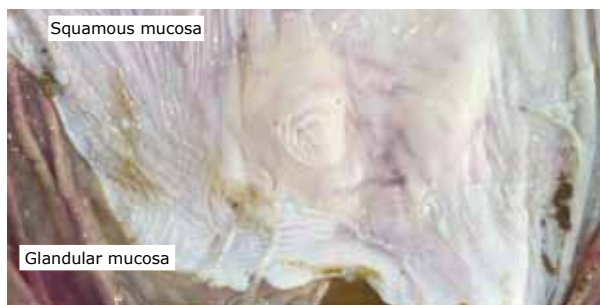

Figure 2. Donkey stomach with equine gastric ulcers syndrome and parasites forms of *Gasterophilus* sp.

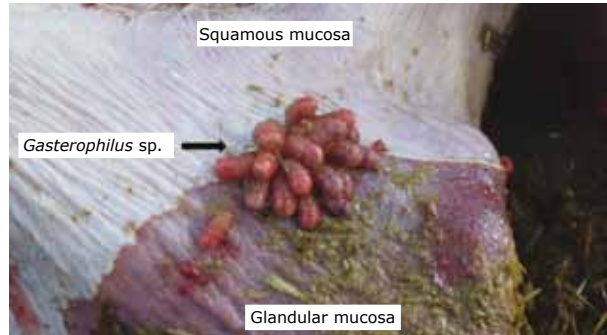

Figure 3. Donkey stomach with equine gastric ulcers syndrome with extensive erosions

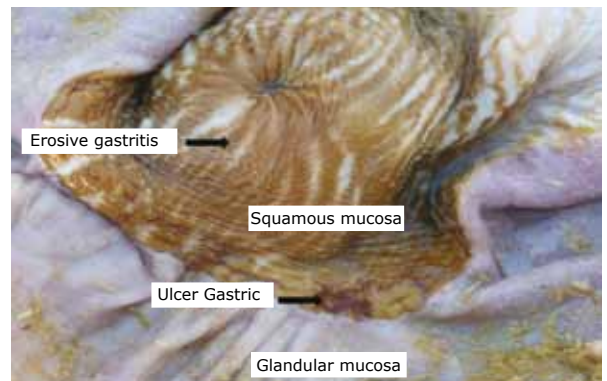
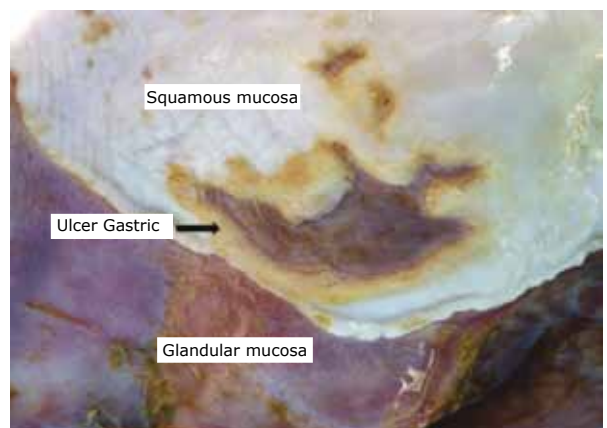

Figure 4. Donkey stomach with equine gastric ulcers syndrome with extensive ulcers, with areas of deep submucosal penetration. Large, single or multi-focal ulcers



DISCUSSION

A high prevalence (90%) of ulcers and gastritis was found in donkeys during our study. It is important to consider that none of the donkeys had previously presented clinical signs of EGUS. The lesions were necropsy findings. The EGUS characteristic signs described in horses (acute and recurrent colic, diarrhea, rough hair coat, poor appetite, weight loss, attitude changes, depression, and decreased performance) differ from those observed in donkeys. However, the study confirms that gastric ulceration can be prevalent in a group of apparently clinically normal horses (9). In donkeys, ulceration of the nonglandular regions of the stomach is more prominent than the glandular regions and parasitic infestations were frequent (10). This agrees with earlier studies reporting the occurrence of gastric ulcers in 80 to 90% of thoroughbred racehorses (1,4-6). Multiple factors may cause the development of EGUS, which are gender, age, and temperament, exercise intensity, intermittent versus continuous feeding, stall confinement, high concentrate diets, nonsteroidal antiinflammatory agents, parasites (*Gasterophilus* sp., *Habronema muscae*), *Helicobacter* spp. and other bacteria, as well as the management. The clinical and therapeutic management of EGUS in donkeys is similar to that of horses. The first step in treatment is EGUS environmental, nutritional and dietary management; and pain management (NSAIDs) with phenylbutazone (4.4 mg/kg, intravenous [IV]) or flunixin meglumine (1.1 mg/kg, IV). Recently, firocoxib (Equioxx, Merial Limited; Duluth, Georgia), a new cox-2 inhibitor NSAID, was approved for treatment of lameness in horses (1). Gastric ulcers were not detected in horses administered with firocoxib (0.1 mg/kg, orally, every 24 hours, for 30 days) (1). Omeprazole oral paste (4 mg/kg, orally, every 24 hours) inhibits gastric acid secretion for 24 hours in horses (1). Ranitidine hydrochloride (6.6 mg/kg)

is four times more potent than cimetidine. Sucralfate and bismuth subsalicylate are two compounds that bind to stomach ulcers and promote healing. Misoprostol (5 mg/kg, orally) increased stomach pH and inhibited gastric acid secretion for 8 hours. Prokinetic agents Bethanechol (0.25 mg/kg, IV) and erythromycin lactobionate (0.1 and 1.0 mg/kg, IV). In conclusion, we reported gastric ulcers syndrome in donkeys in Spain, as a preliminary study. In the literature gastric ulcers syndrome has been described in donkeys and it needs further studies to elucidate gastroendoscopy through the etiology and pathogenesis of gastric ulcers syndrome in donkeys.

REFERENCES

1. Videla R, Andrews F. New perspectives in equine gastric ulcer syndrome. *Veter Clin N Am.* 2009;25:287-8.
2. Andrews FM, Buchanan BR, Elliot SB, Clariday NA, Edwards LH. Gastric ulcers in horses. *J Anim. Sci.* 2005;83(Suppl):E18-E21.
3. Merritt A. The equine stomach: A personal perspective (1963-2003). In 49 Annual Convention of the American Association of Equine Practitioners. New Orleans, Louisiana, 2003.
4. Morales A, Bermúdez V, De Vera M, Contreras M, García-Amado MA, Gueneau P. A multidisciplinary study of gastric ulcers in Thoroughbreds of Venezuela. *Vet Pathol.* 2006;43:5-67.
5. Hepburn RJ. Investigation into the presence of *Helicobacter* in the equine. Stomach by Urease Testing and Polymerase Chain Reaction and Further Investigation into the Application of the ¹³C-Urea Blood Test to the Horse [tesis master of Science in Veterinary Medical Science]. [Virginia, USA]: State University, Leesburg; 2004.
6. Murray MJ. Gastric ulcers in adult horses. *The Compendium.* 1994;16:792-7.
7. Aluja A, Constantino C. Technical of necropsy in domestic animals. 2nd ed. Mexico: Manual Moderno; 2002.

8. Banks W. Veterinary applied histology. 2nd ed. México: Manual Moderno; 1996.
9. Luthersson N, Nielsen KH, Harris P, Parkin TD. The prevalence and anatomical distribution of equine gastric ulceration syndrome (EGUS) in 201 horses in Denmark. *Equine Vet J.* 2009;41(7):619-24.
10. Al-Mokaddem AK, Ahmed KA, Doghaim RE. Pathology of gastric lesions in donkeys: A preliminary study. *Equine Vet J.* 2014:1-5.

